Brain (1997), **120,** 1603–1620

Phantom limbs in people with congenital limb deficiency or amputation in early childhood

Ronald Melzack, Robyn Israel, Renée Lacroix and Geoffrey Schultz

Department of Psychology, McGill University, Stewart Biological Sciences Building, Montreal, Quebec, Canada

Correspondence to: Ronald Melzack, Department of Psychology, McGill University, Stewart Biological Sciences Building, 1205 Dr Penfield Avenue, Montreal, Quebec, Canada H3A 1B1

Summary

*It is widely believed that people who are congenitally limb-deficient or suffer a limb amputation at an early age do not experience phantom limbs. The present study reports on a sample of 125 people with missing limbs and documents phantom experiences in 41 individuals who were either born limb-deficient (*n *= 15) or underwent amputation before the age of 6 years (*n *= 26). These cases provide evidence that phantom limbs are experienced by at least 20% of congenitally limb-deficient subjects and by 50% of subjects who underwent amputations before the age of 6 years. The phantoms are detailed and can be described in terms of size, shape, position, movement and temporal properties. The perceptual qualities of the phantoms can also be described by sensory descriptors and are reported as painful by 20% of subjects with phantoms in the congenital limb deficient group and 42% of young amputees. It is argued that these phantom experiences provide evidence of a distributed neural representation of the body that is in part genetically determined.*

Keywords: phantom limbs; congenital limb deficiency; early childhood amputee; pain

Abbreviation: CHAMP = Canadian Child Amputee Program

Introduction

There is convincing evidence that the neonatal brain is genetically programmed to develop neural networks that subserve the perception of the body. In 1961, Weinstein and Sersen published the first major paper on children with congenital limb deficiency (aplasia), in which they describe five children with phantoms of a limb that was physically absent at birth. This paper was followed by a second which presented evidence of phantom limbs in 13 additional cases of congenital limb aplasia (Weinstein *et al*., 1964). The descriptions of the phantom sensations were similar to those previously reported by adult amputees: the phantoms were perceived as 'real', with a distinct shape and position; seven subjects were able to move the limb voluntarily and four experienced telescoping of the phantom. Poeck (1964) described an additional case of an 11-year-old girl who was born without both forearms and hands. Incredibly, during her first years in school, she had learned to solve simple arithmetic problems by counting on her phantom fingers. In 1967, Vetter and Weinstein reviewed the literature on phantoms of congenitally absent limbs, and tabulated a total of 27 individuals. One of the subjects, described by Sohn (1914), provides the only report of pain in limb-deficient subjects.

Three recent reports provide further evidence of phantoms in people with congenital limb deficiency. Ramachandran (1993) describes a 20-year-old female who, despite congenitally missing arms, experienced very vivid phantom limbs that often gesticulated during conversation. Equally remarkable, Lacroix *et al*. (1992) reported on a girl who was born with a right leg 10 cm shorter than the normal left leg, and who, at the age of 6 years, received a right below-knee amputation. The girl subsequently experienced, at the level of the amputated foot, a phantom foot with toes and a second set of phantom toes attached to the stump. In addition, she felt a second phantom foot including five toes and a calf that extended beyond the stump to the floor and filled the empty space created by the congenitally deficient limb. Sensory inputs from the physical foot prior to amputation, which was locked in an abnormal posture, influenced the shape of the phantom foot, which extended to the floor, indicating an interaction of genetic and experiential determinants. These

three sets of phantoms, which appeared within 3 months after amputation, persisted unchanged up to the last interview when she was 16 years old.

In the third recent report, Saadah and Melzack (1994) presented case histories of four adults with major congenital limb deficiencies who had phantom-limb experiences. Three of them felt phantoms for the first time as adults (at the ages of 16, 29 and 32 years) after minor surgery or injury. A 32-year-old woman, for example, was born with deformed feet attached at the knees. She wore full-length prosthetic legs, but experienced phantom legs only after surgery of a toe at the age of 30 years. Another subject, aged 18 years, had a congenital absence of the left arm below the elbow. At the age of 16 years, she had a horse riding accident. Her artificial limb fell off her stump and she landed on the tip of the stump, producing a small haematoma which was eventually resolved. Shortly after the accident, she developed a constant feeling of a full-length phantom arm, hand and full-length fingers. She had never experienced any phantom feelings before this time.

These observations, taken together, refute the prevailing view that normal, prolonged sensory input from a limb is essential for the establishment of the neural representation of a limb, which is assumed to underlie the body schema and the phantom experience (Simmel, 1958). Because congenitally limb-deficient individuals have had aberrant or no somatosensory experience of the missing body part, the body schema is believed to be undeveloped and therefore the phantom should be absent (Kolb, 1954; Simmel, 1961). More recent arguments have been based on physiological research on neuroplasticity. Skoyles (1990), for example, has argued that changes in cortical maps of the body after excision of a digit make it unlikely that the phantom occurs in aplasics. His argument implies that activity in the somatosensory cortex is sufficient for the experience of a limb and the functional takeover by adjacent structures should obliterate the brain's representation of the deficient limb and preclude the sensation of a phantom limb. While studies of the somatosensory cortex after denervation of parts of a limb reveal a major reorganization of the somatotopic representation at the cortex (*see* review by Kaas, 1991)—typically, the deprived cortex is found to become responsive to new inputs, usually from adjacent body parts—some people with congenital limb deficiency do have phantoms, which may persist for decades.

The persistence of phantom limbs into adulthood in people with congenital limb deficiency indicates that there are limits to the neuroplasticity-induced changes in brain networks as a result of deafferentation. If we propose that the experience of a limb is the result of activity within a distributed network, and not simply a function of activity in a single circumscribed area of somatosensory cortex, then we can understand how phantoms may persist despite localized cortical reorganization. The multiple representation of a body part in a distributed network at several synaptic levels and in parallel projection systems could even explain the multiple phantoms reported by Lacroix *et al*. (1992).

The fact that people with congenital limb deficiency, especially adults, have not lost the sensation of their absent limbs allows the further assertion that part of the neural mechanism that underlies somatic perception is genetically determined and that it persists despite local neuroplasticity in the somatosensory cortex. Changes in innervation due to neuroplasticity may, however, contribute to the fragmentation, telescoping and fading which occur naturally in the phantom limb in children and adults. The changes may also result in the activation of phantom experiences by input from body areas which are represented adjacent, or close, to the input-deprived sensory cortex.

There have been only a few studies on phantoms in people with congenital limb deficiency or an amputation early in life, despite their important implications that the neural representation of the body is, at least in part, genetically determined. This study, therefore, presents detailed information about both congenitally limb-deficient individuals who report phantom limb experiences and individuals who underwent amputations within the first 5 years of life and subsequently developed phantom limbs. In the majority of these cases, the sensations persisted into adolescence and young adulthood. The interviews focused on the age of the subject when the phantom began to appear, its duration and the perceptual qualities of the experience.

Methods

Participants

Recruitment

Participants in the study were recruited from two sources: the Canadian Child Amputee (CHAMP) Program and the Shriner's Hospital for Crippled Children in Montreal. A questionnaire (together with a short article about phantom limb phenomena, based on Melzack, 1990) was mailed to 329 individuals across Canada who are affiliated with the CHAMP Program. Respondents were asked to indicate which limb (or limbs) were missing and whether they were congenitally limb-deficient or had lost the limb after birth. If they had lost a limb, they were asked to indicate their age when the amputation or accident had occurred. Respondents also reported whether they currently felt a phantom limb, had felt one in the past, or had never experienced one. Those who had a phantom limb currently or in the past were asked to describe the perceived body parts, their movement, eliciting circumstances and other properties. Individuals who had experienced a phantom limb in the past noted its duration and their age at the time of its disappearance. Respondents were also asked to describe the appearance of their body in their dreams. At the end of the questionnaire, respondents were asked to state whether they would permit further contact with the experimenters. Completed questionnaires were received from 184 CHAMP individuals. The respondents

consisted of 83 congenitally limb-deficient individuals, 57 individuals who had undergone amputations during the first 5 years of life and 44 individuals who had become amputees at 6 years of age or older.

Participants from the Shriner's Hospital were recruited at a prosthetic clinic which was conducted on a monthly basis. Patients attended this clinic primarily for the prescription and adjustment of artificial limbs. Interviewed patients consisted of 10 congenitally limb-deficient individuals, 22 amputees who had lost limbs at 5 years of age or younger and 14 people who had undergone amputations at 6 years of age or older.

Respondents who were between 6 and 12 years of age and who denied having phantom limbs were also contacted by telephone. This was done in order to see whether any phantom sensations had developed after the time they had filled out their questionnaires (~2 years had elapsed between this time and the final interviewing stage of the study). This procedure revealed the late development of four cases of phantom limbs in congenitally limb-deficient individuals.

Inclusion and exclusion criteria

The criteria for inclusion in the study were that the individuals: (i) were either congenitally limb-deficient or had undergone amputation before the age of 6 years; (ii) were ⩾6 years of age when they were interviewed; and (iii) had experienced phantom limb phenomena continuously or intermittently for ⩾6 months and were able to describe the phenomena with details that included shape, position, movement, sensory descriptors and temporal properties (frequency and duration) of the phantom. Individuals who had not experienced a phantom were also included as part of the sample for the purpose of determining the rate of phantom limb occurrence. Individuals who provided vague recall of possible previous phantom limb occurrences or who noted 'a funny sensation which extended beyond the stump' did not meet these criteria and were excluded from the analyses of the data.

Final participant sample

Following participant recruitment, and after elimination of (i) individuals who did not meet inclusion criteria and (ii) individuals who did not consent to telephone interview, the final sample of participants consisted of 125 individuals. Forty-one of these people, 15 congenitally limb-deficient and 26 early childhood amputees, experienced phantoms and are the subjects of the detailed analyses.

Procedure

Because the subjects obtained through the CHAMP program lived in various provinces across Canada, interviews were carried out by telephone. After completed questionnaires from CHAMP amputees were received, an interviewer telephoned those subjects who both experienced phantoms and consented to provide additional information regarding their phantom sensations. A structured interview was conducted in either English or French, depending on the subject's mother tongue. The experimenter began each interview by verifying whether the subject was still experiencing or had experienced phantom limb sensations in the past. If the response was affirmative, the experimenter obtained information on the exact site, appearance, dimensions, posture and position of the phantom limb. The experimenter also inquired whether a gap existed between the stump and phantom, if one part of the phantom was felt especially vividly, and whether there were any missing parts. In addition, a list of sensory descriptors (e.g. tingling, itching and heavy) was read to the subjects, who were asked to indicate whether they experienced any of them, or any other sensations including pain. Information was also obtained on the phantom limb's duration, frequency and movement, the subject's age when the phantom limb first appeared and conditions which were believed to be responsible for evoking and terminating phantom sensations.

Subjects were asked whether their phantom limb was experienced while wearing or not wearing their prosthesis. Their age at the time they received their first prosthesis was noted. A detailed surgical history was obtained in order to ensure that subjects were congenitally limb-deficient and had not undergone an amputation as a result of a congenital deformity. If they had, they were placed in the amputee group. Additional background information was often acquired from the individual's parents, usually to confirm the subjects' recollections of their perceptions at an early age. Further telephone calls were made during the 2-year period of data collection and analysis, to confirm information or receive more details. Nine subjects who had difficulty describing the shape of their phantom were sent a roll of plasticine and asked to produce the shape and return it in a pre-paid container.

Patients who attended the prosthetic clinic at the Shriner's Hospital were approached by the experimenter at the end of their clinic appointment. They, along with their parents, were informed about the nature of the study and were asked whether they wished to participate. If consent was given, the interview proceeded. Subjects were first asked whether they were aware of the phenomenon of phantom limbs. If they answered affirmatively, they were asked whether they had experienced such sensations. If participants had not heard of phantom limbs, they were told the following: 'Sometimes when a person loses an arm or a leg or even sometimes when a person is born missing a limb, he or she feels as through it's still there. Have you ever felt your missing limb?' Individuals who reported the existence of a phantom limb were then questioned further about its appearance and qualities. The protocol used was similar to that employed during the telephone interviews with the CHAMP subjects. Most patients were interviewed individually. Additional information to confirm the subjects' recollections of perceptions at an early age was obtained by questioning the parents who accompanied the child to the clinic. Some patients

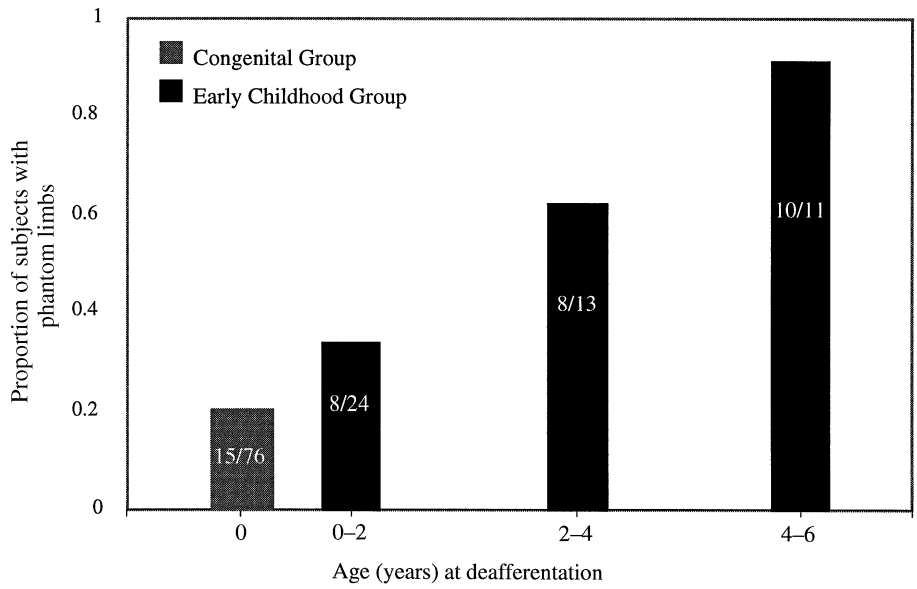

Fig. 1 Relationship between occurrence of phantom limbs and age at time of sensory deafferentation. The early amputation group was divided into three groups (deafferentation at 0–2, 2–4 and 4–6 years).

received a single interview, while others were followed up on repeated visits to the clinic.

Data analysis

Information from subjects' questionnaires and interviews was categorized for presentation in tabular form. For each of the variables an effort was made to create categories that represented the subjects' experiences. Within this guideline, specific rules to categorize responses were as follows.

For the variable 'time to phantom onset', if a subject gave a range of time (e.g. the phantom limb experiences began at the age of 8 or 9 years), then the midpoint of the time specified was used (8.5 years in the above example). For the congenitally limb-deficient group, the subject's birth date was used as the starting point in the calculation. For the early-childhood amputee group, the date of the amputation was used.

For the variable 'frequency', the subject's response that best fit one of the categories 'daily', 'weekly', 'monthly', or 'yearly' was used. If the person gave a response that indicated variation over time (e.g. phantom sensations used to occur weekly but now occur daily), then the category that best represented the most current frequency was used.

For the variable 'duration', if the subject's response spanned more than one category (e.g. the experiences sometimes last for seconds, but other times last for hours), then the category that represented the longest time was used. A subject was classified as having experienced phantom limb pain if they reported at least one clear episode where they had pain in their phantom limb. If a person did not report phantom limb pain, but described his or her phantom by using words that clearly imply discomfort, or 'pain related' words such as 'pricking', 'tender', 'bruised' and/or 'stinging', then that subject was classified as having pain-related sensations.

For the variable 'movement', the response was categorized as 'voluntary movement' if the person could move the phantom limb either mentally or as a result of moving stump muscles. The response was categorized as 'involuntary movement' if the subject described reflexive movement or movement that could not be controlled by the subject.

Additional χ^2, correlation and multiple correspondence analyses were used to examine the relationships among variables. In particular, results are reported separately for congenitally limb-deficient individuals and early-childhood amputees.

Results

Fifteen of the 76 participants (19.7%) with congenital limb deficiency met the criteria for the experience of a phantom limb, whereas the other 61 subjects reported that they had never felt a phantom. In comparison, a significantly larger proportion, 53.1% (26 of 49), of the group of individuals who had undergone limb amputation before the age of 6 years reported phantom limb experiences ($\chi^2 = 15.01$, $P < 0.0005$). When subjects in the early-childhood amputation group were further divided according to amputation age and plotted next to the congenital group (*see* Fig. 1), it is clear that the proportion of subjects who report phantoms rises linearly as a function of age.

Table 1 provides a summary of the information obtained from the participants. The average age of the subjects at the time of the first questionnaire or interview was 14.7 years, with no significant difference in age between the congenital and early childhood groups ($t = 0.25$, $P > 0.80$). The table also shows that the average time to phantom onset was

Table 1 *Summary of participant information*

Variable	Group		
	Congenital	Early amputation	Combined
Number of subjects	15	26	41
Age (mean, years)	14.9	14.5	14.7
Time to phantom onset (mean, years)	9.0	2.3	4.9
Site			
Arm	15	5	20
Leg	3	21	24
Side			
Left	9	12	21
Right	2	11	13
Both	4	3	7
Gender			
Male	6	17	23
Female	9	9	18
Frequency			
Daily range	5	5	10
Weekly range	4	7	11
Monthly range	4	7	11
Yearly range	1	3	4
Duration			
Seconds range	6	6	12
Minutes range	5	15	20
Hours range	4	5	9
Pain			
Phantom pain	3	11	14
No phantom pain	8	11	19
Pain related	4	4	8
Movement			
Voluntary	9	16	25
Involuntary	9	4	13
No movement	1	4	5
Tension			
Tense	1	2	3
Relaxed	9	16	25
Both	5	2	7
Prosthesis			
Prosthesis on	1	6	7
Prosthesis off	12	15	27
Either on or off	2	3	5

significantly longer for the congenitally limb-deficient group when compared with those subjects with amputations in early childhood ($t = 7.55$, $P < 0.0001$). In fact, there was a significant negative correlation between the age at which there was disruption of sensory input (calculated as an age of zero for the congenital group) and the length of time from that disruption to the onset of phantom experiences ($r = -0.77$, $P < 0.0001$). In other words, the older a person was when the amputation occurred, the shorter the time to phantom onset. The remainder of Table 1 shows the frequencies of the categories that were found within each variable.

The χ^2 analyses of the frequencies in Table 1 revealed a number of findings: while there was no overall difference in the frequency with which upper or lower limbs were affected, there was a significant interaction between the group to which the subject belonged and the site of the affected limb ($\chi^2 = 17.6$, $P < 0.001$). Specifically, subjects missing upper limbs were disproportionately represented in the congenital group whereas subjects missing lower limbs were disproportionately represented in the group who received amputations during early childhood. The χ^2 analysis also revealed a combined group difference in the frequency of the categories chosen to describe the 'perceived tension' in their phantom. While there have been reports of phantoms locked in abnormal positions (Cronholm, 1951; Katz and Melzack, 1990), the results of this study show that a significant majority of the subjects describe their phantoms as relaxed.

Results also show that 20% of congenital limb-deficient subjects and 42% of early-childhood amputee subjects have pain in their phantom limb, although the majority of the subjects do not report pain. An additional 27% of the congenital subjects and 15% of the early-childhood amputees used pain related descriptors but did not specifically state that they had pain. There were a significantly greater number of subjects who could voluntarily move their phantom when compared with those who had no movement or those whose phantoms moved only on an involuntary basis ($\chi^2 = 17.2$, $P < 0.001$). Interestingly, there were significantly more subjects with missing limbs on the left side of the body than those with amputations on the right side or both sides ($\chi^2 = 7.2$, $P < 0.05$). Finally, a χ^2 analysis indicated that a significant proportion of subjects experience their phantom predominantly while not wearing a prosthesis. All other χ^2 analyses yielded non-significant results.

While χ^2 analyses were used to probe for potential relationships between the type of limb-absence and the variables presented in Table 1, it is not practical to present the results from all possible combinations of variables taken pairwise. An easier and more graphic representation of the relationships among variables can be obtained through the use of multiple correspondence analysis.

Multiple correspondence analysis is a descriptive multivariate technique that provides a two-dimensional graphical display of cross-tabular data along with associated statistics (Greenacre and Blasius, 1994). This graphical display permits the identification of similar variable categories because the degree of similarity is represented by the proximity of the points in the display. For this analysis, the multiple correspondence analysis was computed on the basis of an indicator matrix derived from variable categories. Following an initial computation, it was found that a single point, 'Arm and leg', was an outlier with respect to the remaining points. In order to remove the skewing effect that can be caused by an outlier (Greenacre, 1994), a second multiple correspondence analysis computation was performed without the category 'Arm and leg'. Subsequently, the category 'Arm and leg' was plotted as a supplementary point, i.e. it was plotted within the two-dimensional space without contributing to the formation of that space. In order to further improve the overall accuracy of the graphical display, a procedure introduced by Benzécri in 1979 was also carried out (for details, *see* Rovan, 1994).

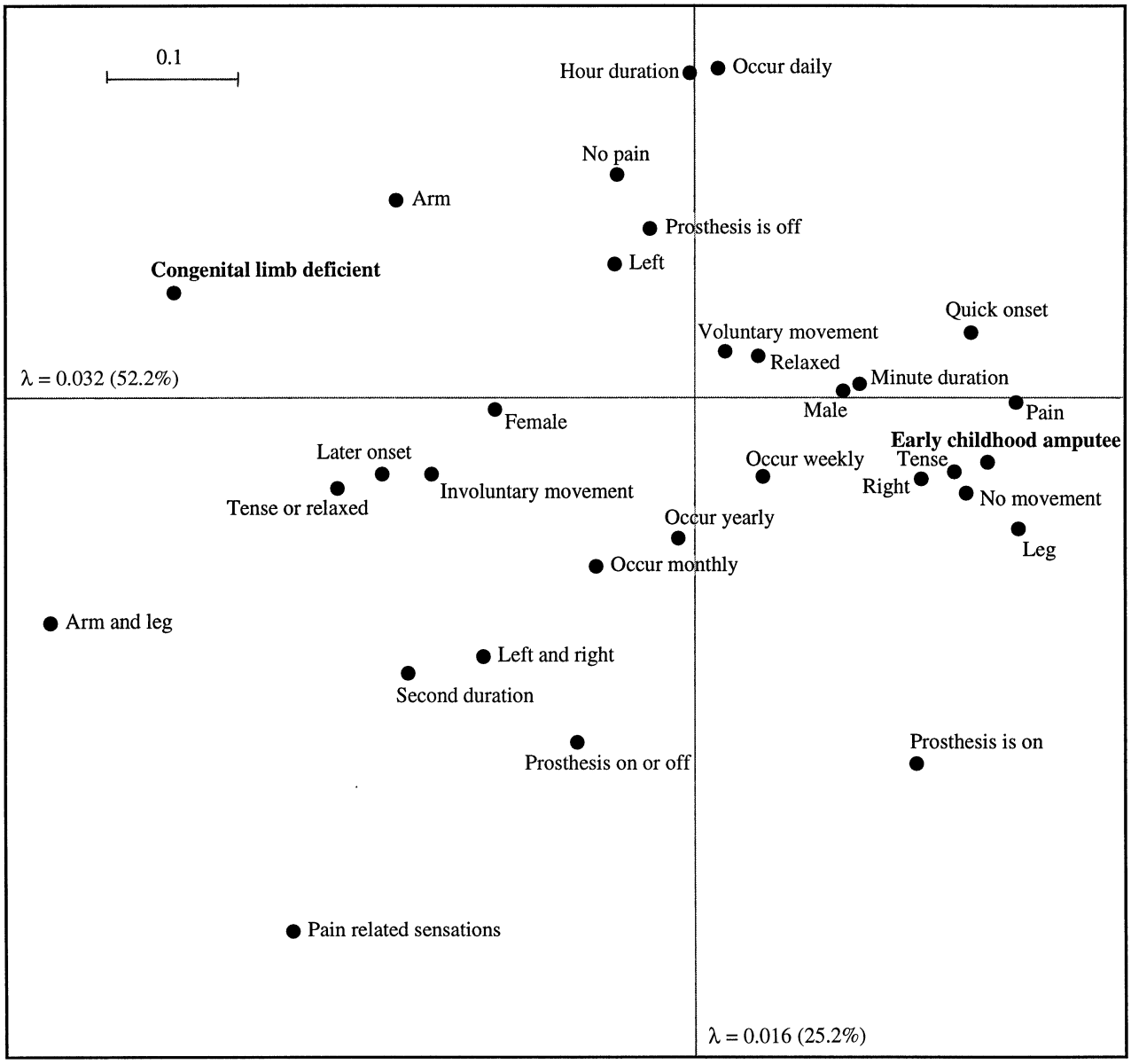

Fig. 2 Two-dimensional plot of the multiple correspondence analysis showing relative associations between properties of phantom limbs.

Figure 2 shows the plot of the variable categories on the first two dimensions of the results. These two dimensions represent 77.4% of the variability in the data. From Table 2 it can be seen that the primary dimension (or axis) pulls apart the points representing the congenitally limb-deficient group and the early-childhood amputee group thus indicating that these two groups have different experiences of their phantom limb. The early-childhood amputees appear to have proportionately more experiences in which the phantom has a quick onset (as mentioned previously), is tense, painful and does not move. Also, the early-childhood amputees have proportionately more missing limbs on the right side of the body that involve the arm rather than the leg.

Finally, Table 2 provides brief descriptions of the subjects' phantom experiences. These cases underscore the remarkable richness of the phantom experiences.

Discussion

The results show that ~20% of people born with congenital limb deficiency develop a phantom of the missing limb and ~50% of children who lose a limb at the age of 5 years or younger develop a phantom limb. These observations contradict the widespread belief that phantoms do not exist in people with congenital limb deficiency and only rarely appear after amputation at an early age. The results also have important implications for understanding the processes involved in the perceptions of our body as well as the development of those perceptions. We experience a world composed of meaningful entities including our own body, yet amputees tell us that those experiences can, at times, be at great odds with the actual physical world. The unique circumstance of the amputee, then, offers a window through which to view the relationship between perceptual experience

Table 2A *Descriptions of the phantom limbs reported by subjects with congenital limb-deficiency (subjects C-01 to C-15)*

Subject, sex/age (years)	(1) Nature of limb deficiency	(2) Age at phantom onset (3) Description of phantom	(4) Frequency (5) Duration (6) Phantom onset and offset factors
C-01, M/11	(1) Malformation of the left arm, with a stump ending at the elbow. A tiny finger bud extends slightly from the stump. The intact right arm is rarely used, because of muscular weakness. C-01 is incapable of walking, although he uses his legs, particularly his feet, to grasp and lift objects.	(2) PH onset at 4–5 years. (3) PH thumb and three PH fingers of normal shape, size and length. No finger is felt more vividly than another. No gap between the stump and PH. Lacks forearm. PH fingers are relaxed; they can either be curled in a fist (i.e. if C-01 uses the control on his wheelchair) or out straight. Movement of all PH fingers (e.g. wiggling) also occurs when thinking about it. Feels position but no other sensations or pain.	(4) Occurring every 2 days when he thinks or talks about his PH fingers. (5) Lasting ~1 min. (6) C-01's PH fingers are usually present, but he particularly feels them, and is aware of their presence, when he thinks or talks about them. They disappear when C-01 distracts himself and thinks of other things. C-01 does not wear a prosthesis.
C-02, F/11	(1) Missing left arm below elbow.	(2) PH onset at 8 or 9 years. (3) PH arm, hand and five fingers. PH arm feels curved in shape and is of normal size and length. PH fingers are of normal shape, size, and length. PH arm is felt most vividly. No gap. PH arm and fingers feel relaxed. They can be either straight or bent. C-02 is unsure how she is able to move them (e.g. she claims that when she makes a fist with her right hand, her left PH hand does the same). No involuntary movement. Pricking, tenderness, numbness, and coldness are felt in C-02's PH arm and fingers. Itchiness, 'pins and needles', and bruised sensations can be sensed only in her PH arm. Pain can be felt in C-02's PH arm and fingers only if she bangs her 'funny bone'.	(4) Occurring at least once or twice per day. (5) Lasting 1–3 h. (6) PH limb is felt when prosthesis is removed. PH usually occurs while C-02 engages in an activity (e.g. bicycle riding, dancing, swimming, throwing a soccer ball). Can also occur by thinking or talking about it, when she's angry (e.g. she feels a PH fist), when she's worried or nervous, when she rubs, tickles, or squeezes her stump, and when it's cold outside. PH limb goes away spontaneously when C-02 relaxes with a book or board games. Also disappears if she touches her stump and it's not cold outside.
C-03, M/11	(1) Missing left arm below elbow. Five finger buds extend from his stump.	(2) PH onset at 9 years. (3) PH hand with four fingers. Remainder of missing arm is absent. PH index finger is felt most vividly. PH fingers are normally shaped. PH index is longest, PH thumb is second longest, and last two fingers are shortest and both the same length. No gap. PH hand feels mostly tense, while PH fingers feel relaxed and are usually straight. However, PH fingers can also bend slightly, and PH hand sometimes feels cupped as though he were trying to drink from it. Involuntary movement of PH hand and fingers (e.g. they stretch up in order to catch a ball). Warmth and itchiness are felt in PH hand. Tightness and tenderness are sensed in PH fingers. No pain is experienced.	(4) Occurring about every 2 months. (5) Lasting seconds (6) PH sensations usually occur while wearing his prosthesis. C-03 likens his prosthesis to a glove, which envelops his life-like PH hand. PH hand primarily occurs while playing sports (e.g. basketball, football) and attempting to catch a ball; his PH hand reaches out for it. While running in soccer, C-03 feels his PH hand propelling his motion. Thinking about his PH can occasionally trigger index finger only. PH disappears when his prosthesis comes in contact with a ball he's trying to catch or another player, or when he touches his stump.
C-04, F/11	(1) Missing left hand, has five tiny fingers at the end of her stump.	(2) PH onset at 6 or 7 years. (3) Five PH fingers of normal shape. Thumb and little finger are of normal length and are felt most vividly; other three fingers are shorter than usual. Remainder of hand is absent. No gaps although only her middle PH finger feels like a direct extension from her real middle finger; other PH fingers don't feel as strongly attached. PH fingers feel tense, particularly her thumb and little finger. PH thumb is usually straight and faces inward; remaining fingers are usually curled. When C-04 moves her wrist, her PH fingers move along with it. When C-04 tightens her wrist, her five fingers become curled in a fist. Talking about her PH induces a swaying motion in her thumb, the only PH finger that moves involuntarily. Tingling, itchiness, coldness, and tickling are sensed in C-04's PH fingers. 'Irritating and stinging' pain affects C-04's PH fingers. Pain arises when C-04 thinks about, or moves, her PH fingers for a long time. Disappears when she stretches her arm and thinks about other things.	(4) Occurring daily but more often in the morning, when C-04 has time to rest. (5) Lasting 3–5 min (after which they can recur). (6) PH fingers occur more often when C-04's prosthesis is removed, and when the weather is cooler (e.g. winter). They can be elicited spontaneously (e.g. while reading a book), by thinking or talking about them, by stress or worry (e.g. C-04 felt them during a concert in which she performed), and by touching/rubbing/banging her stump. C-04 also feels her PH fingers while resting, running, or playing sports. They disappear when C-04 is distracted or when she touches her actual fingers.

Continued on next page

Table 2A *Continued*

Subject, sex/age (years)	(1) Nature of limb deficiency	(2) Age at phantom onset (3) Description of phantom	(4) Frequency (5) Duration (6) Phantom onset and offset factors
C-05, M/12	(1) Missing left arm from shoulder level. Has a deformed right arm which ends at elbow level and lacks an elbow joint. It consists of a short arm, a small hand, and the thumb, index, and middle fingers.	(2) PH onset at 9 years. (3) Complete left PH arm, hand, and five fingers of normal shape, size, and length. PH persisted for 2 years and disappeared at 11 years of age. C-05 reports that all parts of the PH limb were felt equally vividly. No gap. PH arm and fingers felt relaxed. They could be either straight or bent. C-05 was able to control the movement of his PH limb by thinking about it (e.g. he could voluntarily open or close his PH hand). The position of his arm and fingers could also change involuntarily; his limb would naturally follow the position of his right arm. Felt position but no other sensations or pain.	(4) Occurrence: unsure, although PH sensations occurred more frequently when C-05 was active. (5) Lasting 2 h. (6) PH limb appeared spontaneously, by thinking about it, during exercise or playing (e.g., wrestling, playing Nintendo), and possibly by stress. C-05 always experienced his PH limb while not wearing his prosthesis. PH sensations would disappear spontaneously. They ceased entirely at 11 years of age.
C-06, F/13	(1) Missing left hand.	(2) PH onset at 7 years. Was doing gym when she first felt PH sensation. (3) PH hand and five fingers of normal shape, size, and length. All parts are equally vivid. No gap. PH hand feels relaxed; PH fingers are usually bent. C-06 can open and close her hand by moving her stump muscles. Coldness is felt in C-06's PH hand during the winter. No pain is experienced.	(4) Occurring several (3–4) times a month. (5) Lasting minutes. (6) PH hand is felt more often when prosthesis is removed. Evoked during gym, by thinking about gym, by touching or hitting her stump, or spontaneously when C-06 is active. PH hand is felt more often during the winter. PH hand disappears if C-06 stops thinking about it or if she touches her stump.
C-07, F/13	(1) Missing left arm below elbow.	(2) PH onset at ~10 years. (3) PH forearm, hand, and five fingers of normal shape,size, and length. PH hand is felt most vividly. No gap. PH arm is usually extended straight out. PH hand feels relaxed and can be either open or closed. C-07 can move her PH arm, hand, and fingers by manipulating her stump muscles. Involuntary movement of PH arm, hand, and fingers also occurs. No sensations or pain are experienced in her PH arm.	(4) Occurring every 2 months (PH sensations were initially felt once every 2 weeks, and then diminished to once a month (5) Lasting 30 s. (6) Experiences PH arm when not wearing her prosthesis. PH sensations can occur spontaneously, when C-07 attempts to grasp an object, when she hits her stump, and when she is tired. Bad weather can also trigger PH arm. PH sensations disappear as soon as C-07 attends to her stump and focuses on it.
C-08, M/14	(1) Missing right arm below elbow.	(2) PH onset at ~12 years. C-08 recalls that the weather was rainy when his PH hand was first felt. He initially responded to the sensation by asking his mother whether he was going to grow an arm. (3) PH hand and four or five fingers (unsure of exact number, but definitely feels thumb and index fingers). Hand is normally shaped, but fingers are smaller and shorter than normal. Palm of his hand is felt most vividly. Lacks forearm. PH hand curves inward, directly extending from his stump, which also curves inward. PH hand is always relaxed and open, and PH fingers are relaxed and slightly bent. PH hand and fingers are stationary. C-08 feels capable of moving his PH hand to grasp objects, but no movement ensues. Experiences mild PH pain in his hand and fingers, but feels it mostly in his palm. Pain initially began at the time of PH onset. PH pain occurs spontaneously, and under similar circumstances as the non-painful PH. PH pain generally occurs once a week and lasts ~30 s.	(4) Occurring once per week. PH hand initially occurred one to two times per week. (5) Lasting ~1 min. (6) Experiences PH hand when his prosthesis is removed. Primarily evoked by rain, or upon awakening from a dream in which he appears with two normal hands. C-08 has these dreams once a week; upon remembering them in the morning, he feels his PH hand. PH hand can also occur spontaneously, e.g. while watching TV, while playing with his friends and looking at their arms, by thinking or talking about it, and by squeezing or banging his stump. C-08's PH hand disappears when he realizes that he can't make use of it. It also vanishes spontaneously or by touching his stump.

and sensory/environmental input and to point to central mechanisms for the explanation of phantom experiences.

While it has been argued that the descriptions of phantoms provided by young children cannot be trusted—perhaps due to the belief that children cannot differentiate between imagination and reality, or they simply want to appear

Table 2A *Continued*

Subject, sex/age (years)	(1) Nature of limb deficiency	(2) Age at phantom onset (3) Description of phantom	(4) Frequency (5) Duration (6) Phantom onset and offset factors
C-09, F/15	(1) Missing left arm below elbow and last two fingers of right hand. C-09 is also missing her left foot, as well as her right leg above knee level. She underwent separate amputations before 2 years of age, due to congenital malformation of her lower extremities. PH sensations were never experienced in C-09's legs.	(2) PH onset: cannot recall exactly, but claims that PH sensations first occurred during the first 5 years of her life. They began at about the same time on both sides. (3) Left PH forearm, hand, and five fingers of normal shape, size and length. PH of last two fingers of right hand: normal shape, size, and length. Left PH hand was felt most vividly. No gaps. Left PH forearm and fingers, and right PH fingers, were generally relaxed and bent. C-09 felt as though she could move the PH limbs of both sides, but described this ability as a reflex-like motion. Burning, stinging itchiness, bruised, coldness, and aching sensations were experienced in C-09's left PH forearm, hand, and fingers. Numbness was felt in C-09's left PH forearm.	(4) Left PH arm was felt most frequently: occurring two to three times a month. Right PH fingers were felt several times a year. (5) Lasting seconds on both sides. (6) PH sensations were felt more often when her prosthesis was removed. They would generally occur spontaneously, whenever C-09 would attempt to grasp an object (e.g. she recalled that as a youngster, she felt as though she could reach out and touch her toys and dolls). PH sensations also tended to occur when C-09 was in a good mood, or while she was exercising When C-09 attended to the PH sensations and realized her arm and fingers were not really there and that she could not really grasp an object she sought, they would immediately disappear on their own. PH sensations ceased completely at 14 years of age.
C-10, F/15	(1) Small right hand, with five tiny fingers (~2 cm long).	(2) PH onset at ~12–13 years. C-10 was reading a book the first time she felt her PH fingers. (3) Five normally-shaped PH fingers extended directly beyond the tips of her actual fingers. They are bigger and longer than her real fingers. With the combination of her real and PH fingers feels like five normal fingers; no finger is felt more vividly than another. They can be either relaxed or contracted, and their position is concordant with that of her five actual fingers. Whenever C-10 moves her real fingers, her PH fingers automatically move as well. Involuntary movement also occurs. No sensations or pain are experienced.	(4) Occurring daily. Present mostly all the time; however, does not always pay attention to her PH fingers since she's so used to them. (5) Duration variable: can last a few seconds, 15 min, half an hour, or up to several hours. (6) PH fingers are felt when her prosthesis is removed. Evoked while thinking or talking about them, and while playing certain sports, e.g. basketball, especially. Can occur virtually everywhere: in school, while turning the page of a book, while listening to music or watching TV. PH fingers can disappear spontaneously, when C-10 thinks about them, or when she touches her real fingers or touches an object with them.
C-11, F/16	(1) Missing left arm below elbow.	(2) PH onset at ~12 years (3) PH forearm and hand of normal shape, size, and length. No fingers. PH arm is felt most vividly. No gap. PH arm and hand generally feel relaxed. However, when she is nervous or when her stump is tightened up, they are more tense. PH limb may be straight or bent. C-11 can move her PH arm herself by moving the muscles of her stump. Pins and needles are felt in her PH wrist, while coldness can be experienced in the whole PH arm particularly when the rest of her body is cold. No pain is experienced.	(4) Occurring once a month. (5) Lasting seconds. (6) Experiences PH limb while not wearing her prosthesis. C-11 rarely wears one. Occurs when C-11 thinks or talks about it, and when she is relaxed. PH arm disappears on its own when C-11 looks and realizes her arm is not really there. PH sensations can also cease by covering her stump.

Continued on next page

'normal' or that they are more suggestible than adults—the detailed descriptions given by the subjects in this study indicate that the phantoms are valid perceptual phenomena. Participants in both groups had a mean age of >14 years; the youngest subject with congenital limb deficiency was 10 years of age, and the youngest subject who had an amputation in early childhood was 6 years of age. Furthermore, as other observers note (Weinstein *et al*., 1964; Ramachandran, 1993), it is doubtful that child amputees who want to appear 'normal' would describe gaps between stump and phantom; or (as it was found for five subjects in this study) a phantom that resembles the appearance, size, or deformity of their limb prior to amputation; or one whole phantom and a second deformed one. Certainly if it was the intent to appear 'normal', a child would not claim to experience supernumerary appendages.

Why, then, was Simmel (1961) reluctant to give credence to phantom experiences in two subjects in her paper entitled 'The Absence of Phantoms for Congenitally Missing Limbs'? She provides such a careful analysis of her 27 subjects that it is

Table 2A *Continued*

Subject, sex/age (years)	(1) Nature of limb deficiency	(2) Age at phantom onset (3) Description of phantom	(4) Frequency (5) Duration (6) Phantom onset and offset factors
C-12, F/16	(1) Missing elbows and forearms on both sides. Partial hands are located at the ends of her stumps, each having two fingers. Born missing left leg above knee. Amputation of deformed left foot located at stump's end at 11 months. Right leg is shorter than normal and is missing the femur.	(2) PH onset at ~12 years. (3) Left PH arm, hand, and five fingers of normal shape,size and length. PH arm is experienced as a complete or 'third arm' (i.e. not attached to her real arm, but rather beginning at shoulder level) which is folded over her stomach. PH forearm between elbow and hand is felt most vividly. No gap. PH arm, hand, and fingers feel relaxed. PH arm is always bent; PH fingers are always straight. No movement of PH arm or fingers. Similar right PH arm has been experienced, but only three to four times. Left PH foot felt as a vague contour with heel and five toes. Same size as right foot; unsure of its length. Two biggest toes are felt most vividly. Gap between stump and PH foot. PH foot rests relaxed on the ground, at same level as right foot. PH toes are straight and can move involuntarily up and down at times. Tingling and numbness are felt in both her PH arm and foot. Pins and needles are felt in PH elbow. Stinging is sensed in PH elbow and in palm of her PH hand. No pain is experienced.	(4) PH arm and foot occur approx. once a month. PH arm was felt once a week last year. (5) PH arm lasts ~30 s. PH foot lasts ~2 min. (6) PH arm and foot can occur spontaneously, when C-12 is nervous (e.g. felt PH arm during a swimming match), by talking about it, and more likely when she is fit and well-rested. She does not feel them when tired. PH arm tends to be felt particularly when raising her real arm in order to ask a question in class. C-12 often feels PH foot without toes during or after swimming. PH foot is felt mostly while wearing her prosthesis. No prosthesis is worn on her arms. PH sensations disappear when C-12 attends to them and realizes their presence. PH foot can also disappear if C-12 touches her stump.
C-13, M/19	(1) Missing left arm below elbow.	(2) PH onset: 8–10 years (cannot recall exact age). (3) PH forearm, hand, and five fingers of normal size, shape and length. PH hand was felt most vividly. No gap. PH arm was usually tense and straight. PH hand was generally relaxed, and it maintained a cupped position, with his fingers slightly bent. Via the use of his stump muscles, C-13 could elicit slight movement of his PH arm and hand (i.e. a swaying motion). However, he could not open or close his PH hand voluntarily. Involuntary tremor was felt in the PH hand. Numbness was felt throughout C-13's PH arm and hand. Tingling was sensed primarily in his PH hand and fingers, and it would also spread slightly up his arm. Both cramping and an 'arthritic tightness' were felt in C-13's PH fingers. No PH limb pain.	(4) When PH sensations were first experienced, they would generally occur once every 2 or 3 months. PH sensations diminished as C-13 grew older, occurring only once or twice in the last 2 years. (5) Lasting ~5 s. Described by C-13 as 'a flash'. (6) C-13 experienced his PH arm and hand while either wearing or not wearing his prosthesis, but more commonly when he wore it. PH sensations were triggered by activities which required the use of both arms (e.g. climbing a tree, lifting objects). C-13 would also reach out to grasp objects and would then feel his PH arm and hand. PH sensations disappeared spontaneously.
C-14, F/21	(1) Missing left arm below elbow.	(2) PH onset at ~4–5 years; while at kindergarten. (3) PH forearm consisting of a hand and a clump of fingers but unable to say how many there are. No part is felt most vividly. Shape of PH arm and hand is normal; PH fingers lack a defining shape. Size and length of C-14's PH arm, hand, and fingers are normal. No gap. PH arm is usually relaxed; it generally corresponds to the muscular status of the rest of her body. PH fingers are more tense. C-14's PH arm is usually slightly bent although it can straighten or bend further. PH fingers are always slightly cupped. Movement of PH arm is an involuntary reflex (e.g. it straightens by itself). PH hand and fingers are stationary. No PH limb pain or sensations have been experienced.	(4) Occurring once or twice per week. When C-14 was younger, her PH limb used to occur more frequently (twice a day). She would wear her prosthesis more often and for longer periods of time then. (5) Lasting seconds; a 'flash'. (6) PH limb always occurs while not wearing her prosthesis. Occurs ~2 h after her prosthesis has been removed, usually after it has been worn a long time. Generally occurs spontaneously, as a reflex action, when C-14 reaches out to grasp an item with her left arm (e.g. C-14's PH arm has reached out to prevent a cupboard door from slamming shut; her PH hand has tried to catch a falling egg). PH limb disappears after C-14 attempts to use it, and then she realizes that it's not actually there. Also vanishes if C-14 pays attention to it or if she touches her stump.

evident that two of them felt phantoms. The first case, an 8-year old girl initially reported no phantom but in a 2-year follow-up interview (at the age of 10 years), reports that 'she feels the fingers in her stump.' Her father does not believe her and Simmel is inclined not to do so either. She finds it difficult to believe that phantom fingers made their appearance in the 15-

Table 2A *Continued*

Subject, sex/age (years)	(1) Nature of limb deficiency	(2) Age at phantom onset (3) Description of phantom	(4) Frequency (5) Duration (6) Phantom onset and offset factors
C-15, M/26	(1) Right arm ends at wrist level. Normal length from shoulder to elbow, but elbow to wrist is shorter than normal and is slightly curved. Has small hand, 2-inch palm, with one finger; index and middle fingers are attached and form a single finger. Can move his wrist up and down. Left arm ends ~1 inch past elbow. No left hand. Right leg ends above knee. Foot attached at bottom, consisting of three toes. Left leg ends at knee level. Foot attached at bottom, with four toes.	(2) PH onset between 12 and 14 years (told his mother, 'I feel like I have a hand'). (3) Complete right PH hand with five fingers. Index and middle PH fingers exist within his physical finger. PH fingers feel like they are of normal shape, size,and length. Each is felt equally vividly. Can make slight movements of his PH fingers individually. Half-inch gap between wrist and PH hand. PH hand and fingers generally feel relaxed. They can be straight or bent; their position and movement correspond to that of his actual hand. Frequently uses PH thumb to point at people and things (feels PH thumb as sticking out from hand), and has to remind himself that others cannot see his PH thumb.Tingling and pins and needles sensations radiate from C-15's actual hand and extend into PH hand. Pins and needles felt only in thumb and last two PH fingers; tingling shoots into entire PH hand. No pain. No PHs of legs or of left arm.	(4) Occurrence: continuous sensation. (5) Duration: continuous, constant sensation. (6) Since C-15's PH hand feels so natural to him, he is not really aware of it, unless he thinks or talks about it (e.g. it was very salient to him during the interview). C-15 has never worn a prosthesis on his right arm. Discontinued wearing prosthesis on left arm. Currently wears artificial limbs on both legs.

PH = phantom.

Table 2B *Descriptions of the phantom limbs reported by subjects with early amputation (subjects EA-01 to EA-26)*

Subject, sex/age (years),	(1a) Nature of limb amputation (1b) Age at amputation (1c) Cause	(2) Age at phantom onset (3) Description of phantom	(4) Frequency (5) Duration (6) Phantom onset and offset factors
EA-01, M/6	(1a) Bilateral legs below knee. (1b) Amputation at 8 months. (1c) Congenitally deformed feet	(2) PH onset at ~4 years. (3) PH feet and toes are indicated by pointing to them in space below the stumps. PH limb pain is the dominant feature. When EA-01 cries in pain, he points to the empty space occupied by the PH limbs.	(4) Occurring once every 3–4 months. (5) Lasting a few minutes, up to 30 min. (6) Evoked by inactivity, or by maintaining an immobilized position for an extended period of time (e.g. long car ride). Complains about PH limb pain while wearing prostheses. PH sensations disappear by reassuring him, distracting him, banging stumps, and touching or massaging his limbs.
EA-02, F/7	(1a) Right leg below knee. (1b) Amputation at 2 years, 10 months. (1c) Car accident.	(2) PH onset at 3 years. (3) PH leg, foot, and toes. No gap. PH leg is normally shaped; unsure about the shape of PH foot and toes. PH leg and foot are shorter than normal, but PH toes are of normal length. Uncertain about the number of PH toes. PH leg, foot, and toes are relaxed. PH limb is stationary. By manipulating her stump, EA-02 can straighten or bend her PH toes. Has PH limb pain.	(4) Occurrence: continuous. (5) Duration: continuous sensation. (6) Continuous; does not wear a prosthesis.
EA-03, F/8	(1a) Bilateral foot, ankle level. (1b) Amputation at 7 months. (1c) Congenital feet deformities.	(2) PH onset at 7 years. (3) Two PH feet; left one is more vivid. No gaps. Left foot usually has five PH toes; right foot has three PH toes. Left PH foot is normally shaped, but smaller and shorter than right PH foot; it is tense and straight. Right PH foot has curved shape and is relaxed; normal size and length. EA-03 can move only right PH foot by wiggling her right stump. Involuntary movement of both PH feet. Tingling, tenderness, itchiness, and bruised sensations are felt in her PH feet.	(4) Occurring once a week (more often during warm weather (5) Lasting 3 min. (6) Feels PH feet only while wearing prostheses. Occur spontaneously while standing straight. Also evoked by thinking or talking about them. Disappear spontaneously, by banging on her prostheses, or by walking around.

Continued on next page

Table 2B *Continued*

Subject, sex/age (years)	(1a) Nature of limb amputation (1b) Age at amputation (1c) Cause	(2) Age at phantom onset (3) Description of phantom	(4) Frequency (5) Duration (6) Phantom onset and offset factors
EA-04, F/9	(1a) Right arm below elbow. (1b) Amputation at 2 years. (1c) Meat grinder accident.	(2) PH onset: not recalled, but mother said EA-04 had described PH sensations at 3 or 4 years of age. (3) PH of last two fingers; normal shape, size, and length. Forearm, hand and other fingers are absent. Gap between stump and PH fingers. PH fingers are felt in their natural location. PH fingers are straight, relaxed, and stationary. PH finger pain and sharp pains in her stump were experienced in the past.	(4) Occurring once a year. Initially occurred two to three times a week. (5) Lasting 1 min; sometimes 20 s. (6) PH sensations occur spontaneously. Also evoked by thinking about them. Disappear spontaneously, or when EA-04 touches her stump.
EA-05, M/9	(1a) Left leg below knee. (1b) Amputation at 5 years. (1c) Automobile accident.	(2) PH onset at 5 years (a few days after his amputation). Sensations ceased at 7 years of age. (3) PH foot and toes of normal shape, size, and length PH foot was felt most vividly. Unsure about number of toes. Remainder of leg was not experienced. Gap between stump and PH foot; PH foot was felt in its normal location. PH foot and toes were relaxed and straight. Involuntary movement. No pain.	(4) Occurrence: unsure, but claims to have felt PH sensations often. (5) Lasting a few minutes. (6) Occurred spontaneously, more often when not wearing his prosthesis. However, PH foot filled inside of prosthesis. Also evoked by stress or worry. Disappeared spontaneously.
EA-06, M/11	(1a) Left leg above ankle. (1b) Amputation at 4 years, 11 months. (1c) Lawnmower accident.	(2) PH onset at 5 years. (3) Five PH toes of normal shape, size, and length. Remainder of EA-06's foot is not experienced. PH toes are generally telescoped inside his stump. They are straight, relaxed, and pushed inside. By moving his stump, EA-06 can modify their position (i.e. curl them). No pain.	(4) Occurring variable: at least every week, sometimes every 2 days. More often during the summer. (5) Lasting not longer than 10 min. (6) PH onset elicited by movement of stump muscles, thinking about the PH, and worry or anxiety. Experienced while wearing or not wearing his prosthesis. Disappears when EA-06 stops moving his stump or touches it, and when he stops thinking about it.
EA-07, M/12	(1a) Left foot, ankle level. (1b) Amputation at 5 years. (1c) Congenital foot deformity	(2) PH onset at 8 years. (3) PH foot of normal shape and size, but slightly longer. Toes are absent. No gap. PH foot is relaxed and rests on the ground. Capable of moving PH foot up, down, backward, and forward by thinking about it. Pricking, pins and needles, tenderness, numbness, cramping, bruised and aching pain sensations are felt in his PH foot.	(4) Occurring twice per month. (5) Lasting a few minutes. (6) Feels PH foot while resting (e.g. sitting on the couch with his stump not touching the floor). Also occurs spontaneously. Experienced more often when prosthesis is removed and during hot weather. PH sensations disappear when EA-07 rests, touches his stump, or moves his leg.
EA-08, F/12	(1a) Left leg below knee. (1b) Amputation at 4 years. (1c) Congenital club foot.	(2) PH onset: 4 years (immediately after amputation). (3) Feels PH of every part of her missing limb, but not always at the same time. Experiences PH of largest and smallest toes most often. However, by moving her stump muscles, EA-08 can curl her PH toes, and then feels all five PH toes. PH toes are normally shaped, but smaller and shorter than her right-foot toes. Gap between stump and PH leg, and between foot and toes, which are felt in their normal location. PH foot is normally shaped, but smaller and shorter. It is relaxed and straight. Tingling, itchiness, and numbness are experienced in PH leg. Pricking, tenderness, and bruised sensations are felt in PH leg and foot. Stinging is sensed on the bottom of PH foot, and sometimes in PH toes. Pins and needles are felt in big toe or PH leg. Tightness is experienced in PH ankle. Coldness is sensed in PH leg, foot, and toes. PH leg has also felt hot and sweaty during hot weather. An aching is felt in EA-08's PH toes. A stabbing pain is sensed on the bottom of PH foot, as well as in PH toes.	(4) Occurring about five times a week, sometimes even daily. Occurs daily by thinking about PH sensations or by moving her stump muscles. (5) Lasting 1 min. In the past, lasted longer, i.e. ranged from 10 min to 1 h. (6) PH occurs when wearing or not wearing her prosthesis. It occurs spontaneously while swimming, running or taking a bath. EA-08's complete PH limb with two PH toes has occurred several times while sitting. PH toes are also evoked by thinking about them. PH foot and toes can be triggered by moving her stump muscles. PH sensations disappear spontaneously, or by rubbing her stump, by ceasing to move her stump muscles, or by not thinking about them.

Table 2B *Continued*

Subject, sex/age (years)	(1a) Nature of limb amputation (1b) Age at amputation (1c) Cause	(2) Age at phantom onset (3) Description of phantom	(4) Frequency (5) Duration (6) Phantom onset and offset factors
EA-09, F/12	(1a) Right leg below knee. (1b) Amputation at 2 weeks. (1c) Blood clot in right leg impeded circulation. right knee disarticulation at 6 weeks.	(2) PH onset at 6 years. (3) Initial sensation at 6 years of age was of her whole PH leg, with her PH foot and toes. Between the age of 6 and 10 years, felt her PH foot twice, no leg. Recently experienced sensation of the back of her PH leg, though not a complete, well-defined limb. Tingling, stinging, and numbness in PH leg.	(4) PH leg or foot has occurred four times. (5) Lasting 2–3 min. (6) PH occurs when prosthesis is removed. Experiences it spontaneously while sitting down and relaxed. Vanishes when EA-09 shifts her attention to something else.
EA-10, M/12	(1a) Left arm below elbow. (1b) Amputation at 3 years. (1c) Electrical accident.	(2) PH onset at 5 years. (3) PH forearm, hand, and five fingers. No gap. PH fingers are normally shaped, but shorter and smaller, same as pre-amputation length and size. PH hand is closed; PH fingers are bent and contracted. PH limb is stationary. Numbness felt in PH hand. No pain.	(4) Occurring once a week. (5) Lasting a few minutes. (6) PH occurs when anxious or by recalling the accident. Also evoked upon awakening from a bad dream. PH occurs more often when prosthesis is removed. Disappears by touching his stump.
EA-11, M/12	(1a) Left leg; hip disarticulation. (1b) Amputation at 3 months. (1c) Cancer of left thigh while *in utero*.	(2) PH onset: could not recall exactly, but mother reports that EA-11 described numbness in left PH leg at the age of 6 or 7 years. (3) Complete PH limb. Area between PH knee and PH ankle is most vivid. PH limb extends directly from hip. PH knee is located lower than normal (shin level). PH leg is usually smaller and shorter than the intact physical leg. PH foot of normal shape, but smaller (about half size). Usually feels 5 PH toes of normal shape, size, and length. PH limb is semi-relaxed, straight, and stationary. Itchiness and aching pain in PH limb occur often.	(4) Occurring once a week. When it occurs, has a tendency to recur every 1–3 h. (5) Lasting 5 min. (6) PH limb occurs spontaneously, often in bed at night, and when prosthesis is removed. Anxiety or worry can also evoke PH limb. PH limb disappears by touching stump. Also vanishes by calming down.
EA-12, M/12	(1a) Right foot, ankle level. (1b) Amputation at 18 months. (1c) Born missing right femur (congenitally short right leg).	(2) PH onset: unsure, but sensations were very vivid at 7–8 years of age. PH sensations ceased when EA-12 was 11 years old. (3) PH foot and five toes of normal shape, size, and length. No gap. PH toes were felt most vividly. PH foot rested on the ground. Initiated movement of PH by thinking about it. Reported feeling a sharp pain of moderate intensity in PH in the past.	(4) Occurring once a week. (5) Lasting 5 s. (6) Occurred spontaneously while wearing prosthesis. PH vanished by distracting himself (i.e. thinking about something else).
EA-13, M/13	(1a) Left arm below elbow. (1b) Amputation at 5 years. (1c) Meat grinder accident.	(2) PH onset: 5 years (immediately after amputation). (3) PH forearm, hand, and five fingers of normal shape, size, and length. No gap. PH fingers feel contracted, while PH arm is more relaxed. PH arm and fingers can be straight or bent; their position corresponds to that of EA-13's right arm. Involuntary movement. No pain.	(4) Occurrence: virtually a constant sensation day and night (5) Duration: continuous. (6) EA-13 is even more aware of his PH arm when he thinks or talks about, when he touches his stump, and when he is at rest. Also evoked more by cold weather. PH sensations have become more frequent since J.J. stopped wearing his prosthesis this past year. When EA-13 distracts himself and keeps himself busy, he is not as aware of his PH arm.
EA-14, F/14	(1a) Right foot. (1b) Amputation at 18 months. (1c) Congenitally-absent right fibula. Also born with a deformed right foot with two toes.	(2) PH onset: claims that PH sensations began only recently. (3) PH right heel of normal shape and size; does not feel rest of foot. No gap between stump and PH heel. PH heel is relaxed. Capable of moving it by moving her stump muscles. Pricking, tenderness, tightness, and chilling sensations are felt in PH heel. No pain.	(4) Occurrence variable, but generally once per month. (5) Lasting a few seconds. (6) Feels PH heel especially when she thinks about it. Also occurs spontaneously, by talking about it, by tickling her stump, and more so while resting. Experiences PH heel both while wearing and not wearing her prosthesis. PH heel usually disappears when EA-14 stops thinking about it and distracts herself with other matters.

Continued on next page

Table 2B *Continued*

Subject, sex/age (years)	(1a) Nature of limb amputation (1b) Age at amputation (1c) Cause	(2) Age at phantom onset (3) Description of phantom	(4) Frequency (5) Duration (6) Phantom onset and offset factors
EA-15, F/15	(1a) Right arm, elbow level. (1b) Amputation at 2 years. (1c) Lawnmower accident.	(2) PH onset at 5 years. PH sensations ceased at 14 years of age (3) PH hand and fingers of normal shape, size, and length (uncertain about the number of fingers). No gap. Forearm absent. PH hand and fingers were relaxed and open. EA-15 felt she could reach out and grasp objects with her hand by thinking about it.	(4) Occurred once per month. (5) Lasting a few minutes. (6) Occurred spontaneously, or when EA-15 would bang on her stump. Felt when prosthesis was removed, then faded away.
EA-16, M/15	(1a) Right foot, ankle level. (1b) Amputation at 2 years, 10 months. (1c) Lawnmower accident.	(2) PH onset at 3 years. (3) PH of first three toes; normal shape, size and length. Foot absent. Gap between stump and PH toes. Toes are felt in their natural location. They are always elevated above the ground, and feel straight and relaxed. EA-16 initiates movement of his three PH toes by manipulating the bottom of his stump. No sensations or pain.	(4) Occurring about two or three times a month. (5) Lasting ~5 min. (6) PH toes are evoked when EA-16 feels cold (i.e. feels them more often during the winter), by banging on his stump, or may occur spontaneously. Feels PH toes more often when prosthesis is removed. They disappear spontaneously.
EA-17, F/15	(1a) Left foot, ankle level. (1b) Amputation at 4 years. (1c) Congenitally absent left fibula and only three toes on left foot.	(2) PH onset at 4 years (6 weeks post-amputation). PH sensations ceased 6 months after the amputation. (3) PH foot and last three toes of normal shape, size, and length. Contour of PH foot was most vivid. PH toes were felt in their natural location. Position of PH varied—sometimes PH toes were curled under; at other times the PH foot twisted sideways. By manipulating her leg muscles and by thinking about it, EA-17 could wiggle her PH toes. Used to feel PH pain in her foot, described as burning and crushing, as though her PH foot had been in a vise. Pain stopped 2 years after the amputation.	(4) Occurred for several weeks, during a peak period, PH sensations occurred every night. (5) Lasting 1 h. (6) Generally woke up at night and complained of feeling her PH foot. PH foot was also evoked when her leg was sore (i.e. when EA-17 would outgrow her prosthesis). PH toes were felt when her mother would tickle or touch her stump. PH foot was evoked while walking with prosthesis. Disappeared after applying cold water to stump, stroking and massaging her leg, standing upright, and having her mother console her. After several months, PH foot would fade on its own.
EA-18, M/16	(1a) Left foot, ankle level. (1b) Amputation at 4 years. (1c) Lawnmower accident.	(2) PH onset at 10 years. (3) PH foot and five toes of normal shape, size, and length. PH calf muscle is felt most vividly. No gap. PH foot is raised above the ground. PH foot and toes feel relaxed, and are usually straight. They generally move involuntarily. EA-18 can also move his PH foot himself by thinking about it, or by manipulating his stump muscles. No pain.	(4) Occurring once every 2 months; one or two times per week in the past. (5) Lasting ~2 s. In past, lasted ~30 s. (6) Feels PH while not wearing his prosthesis Generally occurs spontaneously, while EA-18 is sitting down and relaxed. Also evoked by thinking about the PH, anxiety, and tickling or bumping his stump. Disappears spontaneously when he thinks about something else, or gets up and moves around.
EA-19, M/16	(1a) Left leg above knee. (1b) Amputation at 3 years. (1c) Farm accident.	(2) PH onset at 6 or 7 years (when EA-19 had chicken pox). (3) PH knee of normal shape, size, and length. No gap. Remainder of limb is not experienced. PH knee has a natural position and is stationary. Tenderness and numbness felt in his knee. Stump pain.	(4) Occurrence: once a month; two or three times a month in the past. (5) Lasting 10 s. (6) Evoked by illness (e.g. a cold), or when stump is banged or injured. Feels PH knee while not wearing his prosthesis. Disappears on its own, or when EA-19 rubs his stump.
EA-20, M/19	(1a) Left arm below elbow. (1b) Amputation at 4 years. (1c) Train accident.	(2) PH onset at ~8 years. (3) Five PH fingers of normal shape, size, and length. No gap. Hand and forearm are absent. Fingers emerge from elbow and are generally straight and relaxed. Involuntary movement. PH described as a tickling sensation. Has stump pain but no PH pain.	(4) Occurring one or two times a year, more in winter. (5) Lasting 5–10 min. (6) PH occurs spontaneously. Also evoked when EA-20 is outside in cold weather. Fades spontaneously. EA-20 does not wear a prosthesis.

Table 2B *Continued*

Subject, sex/age (years)	(1a) Nature of limb amputation (1b) Age at amputation (1c) Cause	(2) Age at phantom onset (3) Description of phantom	(4) Frequency (5) Duration (6) Phantom onset and offset factors
EA-21, M/20	(1a) Right leg below knee. (1b) Amputation at 3 years. (1c) Lawnmower accident.	(2) PH onset at ~4 years. (3) PH of last three toes; normal shape, size, and length. Smallest toe is felt most vividly. Gap between stump and PH toes. PH toes are located where they would normally be. They are generally flat,straight, and tense. PH toes involuntarily conform to the natural movement of EA-21's leg. No voluntary movement of PH. PH pain in toes described as stinging, pressure, and pins and needles.	(4) Occurring whenever EA-21 talks or thinks about his PH. (5) Lasting a few seconds. (6) PH toes occur more often while wearing his prosthesis (appear while talking or thinking about them). They vanish when EA-21 focuses his mind elsewhere. Also disappear by touching his stump.
EA-22, M/21	(1a) Right leg below knee. (1b) Amputation at 4 years. (1c) Gangrene, resulting from a poisonous snake bite.	(2) PH onset at ~4 years (shortly after amputation). (3) PH leg, foot, and five toes of normal shape, size and length. No gap. Position of PH limb corresponds with body movements. Capable of moving PH limb, but unsure how he does so. Experiences numbness in PH limb. Has stump pain, but no PH pain.	(4) Occurrence: not available. (5) Lasting ~20 min (<1 hr). Generally lasts as long as EA-22 thinks about it. (6) Elicited by thinking or talking about it, or by banging his stump. Anything resembling a snake also triggers PH. Disappears when EA-22 stops thinking or talking about the PH. Also vanishes by touching his stump.
EA-23, M/21	(1a) Left leg below knee. (1b) Amputation at 4 years. (1c) Farm accident (grain elevator)	(2) PH onset at ~4 years. PH sensations ceased at 6 or 7 years of age. (3) Five toes of normal shape, size, and length. Gap between stump and PH toes, they were felt in their natural location. Toes were relaxed and straight. Capable of moving PH toes by moving stump. No sensations or pain.	(4) Occurrence: at first, felt PH toes every 2 weeks They were later experienced every few months. (5) Lasting a few minutes. (6) PH toes occurred spontaneously. They were experienced more often when EA-23 was at rest and when his prosthesis was removed. Cannot recall what would make PH toes disappear; they seemed to go away on their own.
EA-24, F/21	(1a) Right foot, ankle level. (1b) Amputation at 6 months. (1c) Congenitally fused right knee, which lacked a cap and cartilage around the knee joint.	(2) PH onset: could not recall. (3) PH knee felt at end of stump, and is of normal shape and size. It feels natural and can bend. Also feels PH foot and PH of first four toes, all of normal shape and length. PH foot is smaller. Gap exists between PH knee and PH foot. PH foot is relaxed and rests flat on the ground. PH toes are felt most vividly. Capable of wiggling her PH toes voluntarily, but she is unsure how she does this.	(4) Occurrence sporadic (can occur consecutively for 3 weeks, disappear for a while, then return). (5) Lasting seconds, or at most, minutes. (6) PH sensations occur spontaneously, while standing, sitting, or lying down. Also evoked by fatigue. PH sensations occur when prosthesis is on or off. PH sensations vanish when EA-24 realizes that she is feeling something that is not actually present.
EA-25, M/23	(1a) Bilateral foot, ankle level. (1b) Amputation at 8 months. (1c) Congenitally absent right and left fibulas.	(2) PH onset: cannot recall. (3) Left and right PH feet. Smaller and shorter than normal. No gap. Toes are absent. PH feet are relaxed, dangling slightly above the ground. Has better control over the movement of his left PH foot (via his stump muscle). Involuntary movement of PH feet also occurs. Reported feeling sharp PH pain day before interview; no PH pain prior to this experience.	(4) Occurring weekly. (5) Lasting 15 min. (6) PHs are evoked primarily by thinking about them, as well as during cold weather. Occur while wearing his prostheses. Sensations fade on their own.

month interval between interviews. Yet this is precisely what we observed with several subjects in our study.

Simmel's second subject, a 10-year-old girl who was missing her right hand and all fingers except a rudimentary thumb, states that she 'feels the little finger, like a real little finger, like the (normal) little finger on the other hand' (Simmel, 1961, p. 469). Simmel goes on to say, 'She is quite definite about this, says it is only true of the little finger, not of the others. . . . At the end of the interview, the little girl added, 'I sometimes imagine the other fingers.' Simmel is struck by the girl's insistence that she feels the little finger and imagines the others and admits that 'The 'feeling of the little finger' on voluntary motion of the residual hand-bones sounds like a report of a *bona fide* phantom.' She searches

Table 2B *Continued*

Subject, sex/age (years)	(1a) Nature of limb amputation (1b) Age at amputation (1c) Cause	(2) Age at phantom onset (3) Description of phantom	(4) Frequency (5) Duration (6) Phantom onset and offset factors
EA-26, M/27	(1a) Right leg below knee. (1b) Amputation at 2 years. (1c) Congenital club feet. (Also a left foot amputation, ankle level, at 19 years of age.)	(2) PH onset at 2 years. (3) Feels bottom of right PH foot, and two separate sets of PH toes. No gap. PH foot is usually relaxed. By contracting his stump muscles, EA-26 can voluntarily move his right PH foot up and down, as well as wiggle his PH toes. Tickling, burning, stinging, itchiness, pins and needles, pricking, tenderness, tightness, and aching and stabbing pain are felt in right PH. Moreover, any sensation that is felt in his physical leg extends into his PH foot (e.g. during hot summer periods, his leg becomes sore, and consequently his PH foot feels sore, too).	(4) Occurring daily (usually feels PH when he returns from work at the end of the day). (5) Lasting 20–45 min. (6) Evoked particularly by thinking or talking about it. Also elicited by activity (e.g. excessive walking, running, when EA-26 rubs lotion on the end of his stump. Experiences PH when prosthesis is either on or off (feels PH by putting weight on stumps, such as walking without his prosthesis). Disappears by applying hot water, rubbing leg, removing prosthesis followed by leg elevation, and by ceasing thoughts or discussion of PH.

PH = phantom.

for another explanation in terms of sensory input, ignoring the fact that moving residual bony structures within her stump cannot explain a phantom that projects into space like a physical finger.

It may be, then, that previous reports of phantom experiences were rejected in part because there was no conceptual framework to make sense of the data. Simmel (1961) had espoused the concept that the phantom is produced by the body schema described by Head and Holmes (1911–1912) as the product of continuous proprioceptive and other somatic input. The idea of an innate structure for the neural basis of the phantom was, therefore, not considered. Yet this is precisely where the data point.

To state that there is an innate or genetically determined component to the phantom limbs does not imply that the role of environmental sensory input is irrelevant. Obviously the phantom limb experience is the result of complex processes, otherwise all children who are born with a limb deficiency would either have a phantom or not have one. Indeed the data from our subjects reveal the multifactorial nature of the contributions that produce the phantom.

External factors were found, both 'distal' and 'proximal'. Distal factors included rainy and cold weather conditions ($n = 8$) or, conversely, warm weather conditions ($n = 2$). External factors that could be considered more proximal to the stump were also found. For example, a number of subjects found the phantom to be elicited when the limb stump was bumped, banged or touched ($n = 13$). Similarly, Saadah and Melzack (1994) found that phantoms were elicited in adults for the first time after minor surgery of the stump; curiously, the phantom could be made to disappear with touching or rubbing the stump ($n = 20$).

Even more interesting are those factors that can be classified as internal or, more specifically, cognitive. A number of subjects felt their phantom after merely thinking about it or talking about it ($n = 21$). This suggests that the phantom, like the perception of our body, can become more salient when it is specifically attended to. The phantom was also reported to start while under stress, worry or anxiety ($n = 8$). And finally, a number of subjects noted that their phantom became salient when they were physically active ($n = 11$).

A number of our subjects, both congenitals and amputees, had phantom pain from time to time. It is interesting to note that prior to this study, only one report of phantom limb pain in a congenitally deficient person exists in the literature. Sohn (1914) describes a 19-year-old girl with congenital absence of her forearm below the elbow. At the tip of the conical stump is a tiny hand with rudimentary fingers. He states (p. 960): 'She was free from pain until [the age of 14 years], when she began to complain of sticking pains in the stump. At first the pain was slight, and came at long intervals. Then it began to increase in intensity and frequency, until she was troubled daily with these sharp pains that began in the stump, and radiated downward to the fingers of the hand that she never had. She said: 'If the end of the stump was opened a hand would grow out of it, for I am sure there is something inside which wants to come out. It feels as though a lump inside is struggling to get out and there is this sticking pain which I feel all the way down to my fingers.' The site of the pain varied. About three or four times a week, she felt the pain in the stump only and its duration was 1–2 h. The pain in the fingers was present only two or three times a week, but lasted 3–4 h. [During] these pains she felt that she had two hands of equal size and shape. Very often she felt something going up and down between the elbow and the tips of her fingers. She felt the fingers stiffen out, and then she experienced very much pain.'

While the cause of phantom pain remains a puzzle, it is interesting to note that the multiple correspondence analysis result shows that the points 'no movement', 'tense' and 'pain' are close together, indicating an association between these three variables. This result must be interpreted with care because the stability of the points, i.e. how the relative position of the points would differ in another sample of

subjects, is unknown at present. With this caveat in mind, the association provides fertile ground for speculation. Ramachandran (1996) for example, has recently reported that causing an otherwise locked phantom arm and/or hand to move with the use of an ingeniously simple device—in which a mirror reflects an image of an intact arm to a point in space where the phantom is felt to be located and subsequent movement of the physical arm is also perceived as the phantom moving—resulted in the relief of 'clenching spasms' in four of five subjects in his study. Indeed, we can speculate that 'tension' in the phantom may be the experiential result of motor commands sent to the non-existent arm without appropriate feedback from the arm. And further, that certain types of pain may result when these motor commands are sent in bursts of abnormal activity. It may be important, then, in determining the cause of some types of phantom limb pain, to understand how some amputees can move their phantom simply by volition alone.

The results of this study permit the following conclusions.

(i) *There is a neural representation, or neural network, of the body that, when active, gives rise to perceptual experiences of our body*

This means that the basic experience of the body is not derived from a straight-through information pathway fed by sensory receptors. People can experience limbs that are normal in size and shape even when there is little, disorganized, or no peripheral input. Melzack (1989) has proposed that phantom limbs are produced by a network of neurons, or 'neuromatrix', which consists of loops that integrate the somatosensory thalamus and cortex, the limbic system and the association cortex. It is suggested that sensory input is woven into an ongoing process, but the input does not, by itself, produce the output pattern. In this manner, our body perceptions are fluid, dynamic and constantly changing. The evanescent nature of the phantom thus reveals the way the brain functions. We are rarely aware of a whole body. Some of the subjects felt their phantom (or part of it) for minutes or hours at intervals of weeks or months, yet their perception (even during periods as short as seconds) was described as being real, as 'real' as the intact physical parts of their body. The phantom, like our physical body, is constantly being generated in new positions. Different parts of the body weave in and out of attention. It is constantly being created by the neural network ('neuromatrix') according to the needs of the moment.

(ii) *The representation is distributed*

Three facts suggest that the neural network is distributed. First, phantom experiences in both congenitally limb deficient subjects and young amputees persist despite local somatosensory reorganization that is known to take place following deafferentation. The persistence of these phenomena is contrary to predictions that derive from studies of neuroplasticity (Skoyles, 1990). These studies examine the relationship between the deafferentation of peripheral nerves and the reorganization of the somatosensory cortex. Typically, the deprived cortex is found to become responsive to new input. Thus, according to this idea, sensory input that is simply transmitted to the somatosensory thalamus and cortex should result in the loss of limb sensation because of neuroplastic changes. It does not.

The second line of evidence is that brain damage throughout the parietal lobe can cause various partial 'neglect syndromes' in which portions of the body are ignored as though they are physically absent (Mesulam, 1981). Obviously, then, areas within the parietal lobes normally contribute to the perception of the body and may be considered part of the distributed neural network that subserves it.

Finally, and perhaps most convincingly, numerous cases have been described in which excision of the somatosensory cortex did not prevent the re-appearance of a phantom limb at follow-up (Gybels and Sweet, 1989). Clearly, the somatosensory cortex is not the sole neural substrate.

(iii) *The neuromatrix is, in part, innately determined*

The fact that phantoms are present in virtually all adult amputees provides convincing evidence of a neural network responsible for these experiences. If all congenitally limb-deficient individuals failed to experience phantoms, then it would be likely that the neural network was built up gradually by sensory experience. But the fact is that almost one in five of the congenital limb-deficient participants in our sample did have phantoms. Further, it is possible that even more people in the congenital group could have subsequently developed phantoms. Subjects in another study reported phantoms for the first time when they were in their twenties and thirties (Saadah and Melzack, 1994).

The evidence, taken together, suggests that the neural network that subserves the perception of the phantom limb has both genetic and experiential determinants. The subject described by Lacroix *et al*. (1992), for example, reported that her phantom foot was flat and stuck in a forward position. When her medical records were later examined, they revealed that the foot which was amputated had a flatfoot deformity and that it was locked in an equinovalgus position. Interestingly, when the participant was contacted and questioned about her memories of the foot, which had been amputated years earlier, she remembered her foot to be normal in all respects. It is evident that the early sensory input produced neural changes (memories) of the actual deformity in the somatic neural network without having conscious recall of them. The evidence clearly suggests an interaction of both genetic and sensory determinants.

In summary, the phantom limbs of people with congenital limb deficiency or those who have undergone amputation

early in life reveal the complexity of brain processes that underlie the perceptions of the body-self. They show that the perceptions of the phantom limb, like those of a physical limb, are usually brief and undergo continuous change. It indicates that our perception of our body is not a passive process that merely reflects inputs from the body, but is continuously generated by a distributed neural network in the brain, based on both stable genetic determinants and the highly variable properties of spatial and temporal inputs.

Acknowledgements

We wish to thank Carol Wilkins, Adele Fifield and their colleagues at the CHAMP Program of Canada, and Dr N. Mitchell and his staff of the Amputation Clinic at the Shriners Hospital for Crippled Children, Montreal, Canada. We also wish to thank Deanne Smith for her valuable assistance. This study was supported by Natural Sciences and Engineering Research Council of Canada Grant No. A7891 to R.M.

References

Cronholm B. Phantom limbs in amputees. Acta Psychiat Neurol Scand 1951; Suppl 72: 1–310.

Greenacre M, Blasius J. Preface. In: Greenacre M, Blasius J, editors. Correspondence analysis in the social sciences. London: Academic Press, 1994: vii-ix.

Gybels JM, Sweet WH. Stereotactic mesencephalotomy. In: Gybels JM, Sweet WH, editors. Neurosurgical treatment of persistent pain. Basel: Karger, 1989: 210–9.

Head H, Holmes G. Sensory disturbances from cerebral lesions. Brain 1911–12; 34: 102–254.

Kaas JH. Plasticity of sensory and motor maps in adult mammals. [Review]. Ann Rev Neurosci 1991; 14: 137–67.

Katz J, Melzack R. Pain 'memories' in phantom limbs: review and clinical observations. [Review]. Pain 1990; 43: 319–36.

Kolb LC. The painful phantom. Springfield (IL): Charles C. Thomas 1954.

Lacroix R, Melzack R, Smith D, Mitchell N. Multiple phantom limbs in a child. Cortex 1992; 28: 503–7.

Melzack R. Phantom limbs, the self and the brain (the D.O. Hebb memorial lecture). Can Psychol 1989; 30: 1–16.

Melzack R. Phantom limbs and the concept of a neuromatrix. [Review]. Trends Neurosci 1990; 13: 88–92.

Mesulam M.-M. A cortical network for directed attention and unilateral neglect. [Review]. Ann Neurol 1981; 10: 309–25.

Poeck K. Phantoms following amputation in early childhood and in congenital absence of limbs. Cortex 1964; 1: 269–75.

Ramachandran VS, Rogers-Ramachandran D. Synaesthesia in phantom limbs induced with mirrors. Proc R Soc Lond B Biol Sci 1996; 263: 377–86.

Ramachandran VS. Behavioral and magnetoencephalographic correlates of plasticity in the adult human brain. [Review]. Proc Natn Acad Sci USA 1993; 90: 10413–20.

Rovan J. Visualizing solutions in more than two dimensions. In: Greenacre M, Blasius J, editors. Correspondence analysis in the social sciences. London: Academic Press 1994: 210–29.

Saadah ES, Melzack R. Phantom limb experiences in congenital limb-deficient adults. Cortex 1994; 30: 479–85.

Simmel ML. The absence of phantoms for congenitally missing limbs. Am J Psychol 1961; 74: 467–70.

Simmel M. The conditions of occurence of phantom limbs. Proc Am Philos Soc 1958; 102: 492–500.

Skoyles JR. Is there a genetic component to body schema? [letter]. Trends Neurosci 1990; 13: 409.

Sohn DL. The psychic complex in congenital deformity. N Y Med J 1914; 100: 959–61.

Vetter RJ, Weinstein S. The history of the phantom in congenitally absent limbs. Neuropsychologia 1967; 5: 335–8.

Weinstein S, Sersen EA, Vetter RJ. Phantoms and somatic sensation in cases of congenital aplasia. Cortex 1964; 1: 276–90.

Weinstein S, Sersen EA. Phantoms in cases of congenital absence of limbs. Neurology 1961; 11: 905–11.

Received September 18, 1996. Revised March 25, 1997. Accepted May 3, 1997