

Neuronal networks in children with continuous spikes and waves during slow sleep

Michael Siniatchkin,¹ Kristina Groening,¹ Jan Moehring,¹ Friederike Moeller,¹ Rainer Boor,² Verena Brodbeck,³ Christoph M. Michel,³ Roman Rodionov,⁴ Louis Lemieux⁴ and Ulrich Stephani¹

1 Neuropaediatric Department, Christian-Albrechts-University, Kiel, Germany

2 Northern German Epilepsy Centre, Raisdorf, Germany

3 Functional Brain Mapping Laboratory, University of Geneva, Switzerland

4 Department of Clinical and Experimental Epilepsy, UCL Institute of Neurology, Queen Square, London, UK

Correspondence to: Michael Siniatchkin,
Neuropaediatric Department,
Paediatric Hospital,
Christian-Albrechts-University,
Schwanenweg 20,
D-24105 Kiel,
Germany
E-mail: m.siniatchkin@pedneuro.uni-kiel.de

Epileptic encephalopathy with continuous spikes and waves during slow sleep is an age-related disorder characterized by the presence of interictal epileptiform discharges during at least >85% of sleep and cognitive deficits associated with this electroencephalography pattern. The pathophysiological mechanisms of continuous spikes and waves during slow sleep and neuropsychological deficits associated with this condition are still poorly understood. Here, we investigated the haemodynamic changes associated with epileptic activity using simultaneous acquisitions of electroencephalography and functional magnetic resonance imaging in 12 children with symptomatic and cryptogenic continuous spikes and waves during slow sleep. We compared the results of magnetic resonance to electric source analysis carried out using a distributed linear inverse solution at two time points of the averaged epileptic spike. All patients demonstrated highly significant spike-related positive (activations) and negative (deactivations) blood oxygenation-level-dependent changes ($P < 0.05$, family-wise error corrected). The activations involved bilateral perisylvian region and cingulate gyrus in all cases, bilateral frontal cortex in five, bilateral parietal cortex in one and thalamus in five cases. Electrical source analysis demonstrated a similar involvement of the perisylvian brain regions in all patients, independent of the area of spike generation. The spike-related deactivations were found in structures of the default mode network (precuneus, parietal cortex and medial frontal cortex) in all patients and in caudate nucleus in four. Group analyses emphasized the described individual differences. Despite aetiological heterogeneity, patients with continuous spikes and waves during slow sleep were characterized by activation of the similar neuronal network: perisylvian region, insula and cingulate gyrus. Comparison with the electrical source analysis results suggests that the activations correspond to both initiation and propagation pathways. The deactivations in structures of the default mode network are consistent with the concept of epileptiform activity impacting on normal brain function by inducing repetitive interruptions of neurophysiological function.

Keywords: continuous spikes and waves during slow sleep (CSWS); EEG-fMRI; EEG source analysis; perisylvian region; remote inhibition; children

Abbreviations: BOLD = blood oxygenation dependent; CSWS = continuous spikes and waves during slow sleep; fMRI = functional magnetic resonance imaging; MNI = Montreal Neurological Institute; REM = rapid eye movement; SPM = statistical parametric mapping

Introduction

Epileptic encephalopathy with continuous spikes and waves during slow sleep (CSWS) is an age-related reversible disorder characterized by acquired variable neuropsychological impairment, epilepsy with heterogeneous seizure types, and the presence of the interictal electroencephalographic (EEG) findings of intense sub-continuous paroxysmal activity consisting of spike-wave complexes that usually occupy more than 85% of non-rapid eye movement (REM) sleep (Tassinari *et al.*, 2005). This disorder may be attributed to different aetiologies (symptomatic cases with various lesions, cryptogenic epilepsies and even idiopathic cases, for example, in the form of Landau–Kleffner syndrome or atypical benign partial epilepsy of childhood). CSWS is usually associated with manifold psychomotor and cognitive deficits (auditory agnosia, acquired aphasia, dysfunctions of the frontal lobe and short-term memory deficits, pseudo-bulbar palsy, global mental deterioration, impaired spatial orientation, apraxia and hemineglect, psychotic states and autistic features, attention deficit and hyperactivity and aggressiveness) (Roulet Perez *et al.*, 1993; Maquet *et al.*, 1995; Shafir and Prensky, 1995; Galanopoulou *et al.*, 2000; Eriksson *et al.*, 2003; Scholtes *et al.*, 2005; Deona and Roulet, 2006; Holmes and Lenck-Santini, 2006; Metz-Lutz, 2009). Despite this heterogeneity, however, most patients with CSWS demonstrate common features: substantial increases in paroxysmal activity during sleep and a complex morphology of interictal epileptiform discharges with bilateral and diffuse spikes and waves, which tend to generalize (Tassinari *et al.*, 2005; Nickels and Wirrell, 2008). Although in the first description of the epileptic encephalopathy with CSWS by Patry *et al.* (1971), the authors suggested a ‘particularly active synchronizing system’ that ‘could account for extreme activation of the spike and wave spikes’ during sleep, and different studies have provided arguments in favour of secondary bilateral synchrony (Gaggero *et al.*, 1995; Maquet *et al.*, 1995; Morrell *et al.*, 1995; De Tiege *et al.*, 2004; Luat *et al.*, 2005), understanding of the underlying mechanisms is very limited.

Simultaneous recording of EEG and blood-oxygenation level-dependent (BOLD) functional magnetic resonance imaging (EEG-fMRI) is a non-invasive technique that allows evaluation of haemodynamic changes in the brain correlated with pathological activity on the scalp EEG acquired within the scanner (Hamandi *et al.*, 2005; Gotman *et al.*, 2006; Laufs and Duncan, 2007). Due to whole-brain coverage and relatively high spatial resolution, this technique is able to characterize neuronal networks associated with EEG patterns in a unique way (Vulliemoz *et al.*, 2009). BOLD patterns reflecting networks have been demonstrated in relation to primary and secondary generalized epileptiform activity (Aghakhani *et al.*, 2004; Hamandi *et al.*, 2006; Moeller *et al.*, 2008) and hypersarrhythmia (Siniatchkin *et al.*, 2007b). In focal

epilepsies, the EEG-fMRI has revealed not only neurometabolic changes in brain regions corresponding to the spike localization, but also in functionally significant brain areas remote of epileptic activity (Kobayashi *et al.*, 2006; Jacobs *et al.*, 2007, 2009; Laufs *et al.*, 2007). The addition of electrical source imaging may allow the identification of areas of spike generation and propagation and therefore enhance the interpretation of fMRI results (Boor *et al.*, 2007; Grova *et al.*, 2008; Groening *et al.*, 2009; Vulliemoz *et al.*, 2009, 2010a).

Here, we characterized the neuronal networks associated with epileptic spikes using simultaneous EEG-fMRI recordings in children with epileptic encephalopathy and CSWS during drug-induced sleep. The study aims to distinguish brain areas which are common across patients and are involved in the pathological process underlying CSWS.

Materials and methods

Subjects

Between May 2005 and June 2009, patients with CSWS were recruited in the Northern German Epilepsy Centre, Raisdorf and in the University Hospital of Paediatric Neurology, Kiel, Germany. The inclusion criteria were: (i) the presence of epileptic activity during >85% of non-REM sleep; (ii) new diagnosis of epileptic encephalopathy with CSWS before specific treatment of this condition; and (iii) bilateral and diffuse EEG abnormalities (Fig. 1). Diagnosis was made according to the International League against Epilepsy 2001 classification scheme (Commission on Classification and Terminology of the International League against Epilepsy, 2001). Eight boys and four girls with CSWS, aged between 3 and 13 (mean 8.5 ± 2.8 years) at the time of recording, met the criteria. The clinical and demographic characteristics of the group are shown in Table 1. All patients were investigated in the neuroimaging laboratory of the University Hospital of Paediatric Neurology, Kiel.

The neurological examination and structural MRI (high-resolution T₁-, T₂-, fluid attenuated inversion recovery T₂- and diffusion-weighted imaging) were performed before inclusion in the study. Routine sleep EEGs under sedation (32 electrodes according to the International 10–20 System, the same sedation as for EEG-fMRI, i.e. oral chloral hydrate 75 mg/kg) were recorded 1–2 days before the EEG-fMRI investigation and were evaluated by at least two specialists independently, who confirmed the presence of CSWS. All patients presented with neuropsychological abnormalities: global retardation, aphasia, attention-deficit hyperactivity disorder, conduct disorder and autism (Table 1). None of the children suffered from Landau–Kleffner syndrome. All children were sedated 30 min before MRI scanning and the EEG-fMRI recordings were performed when the children were asleep. Foam pads were used to help secure the EEG leads, minimize motion and improve patient comfort. A paediatrician was present throughout the examination. The study was performed according to

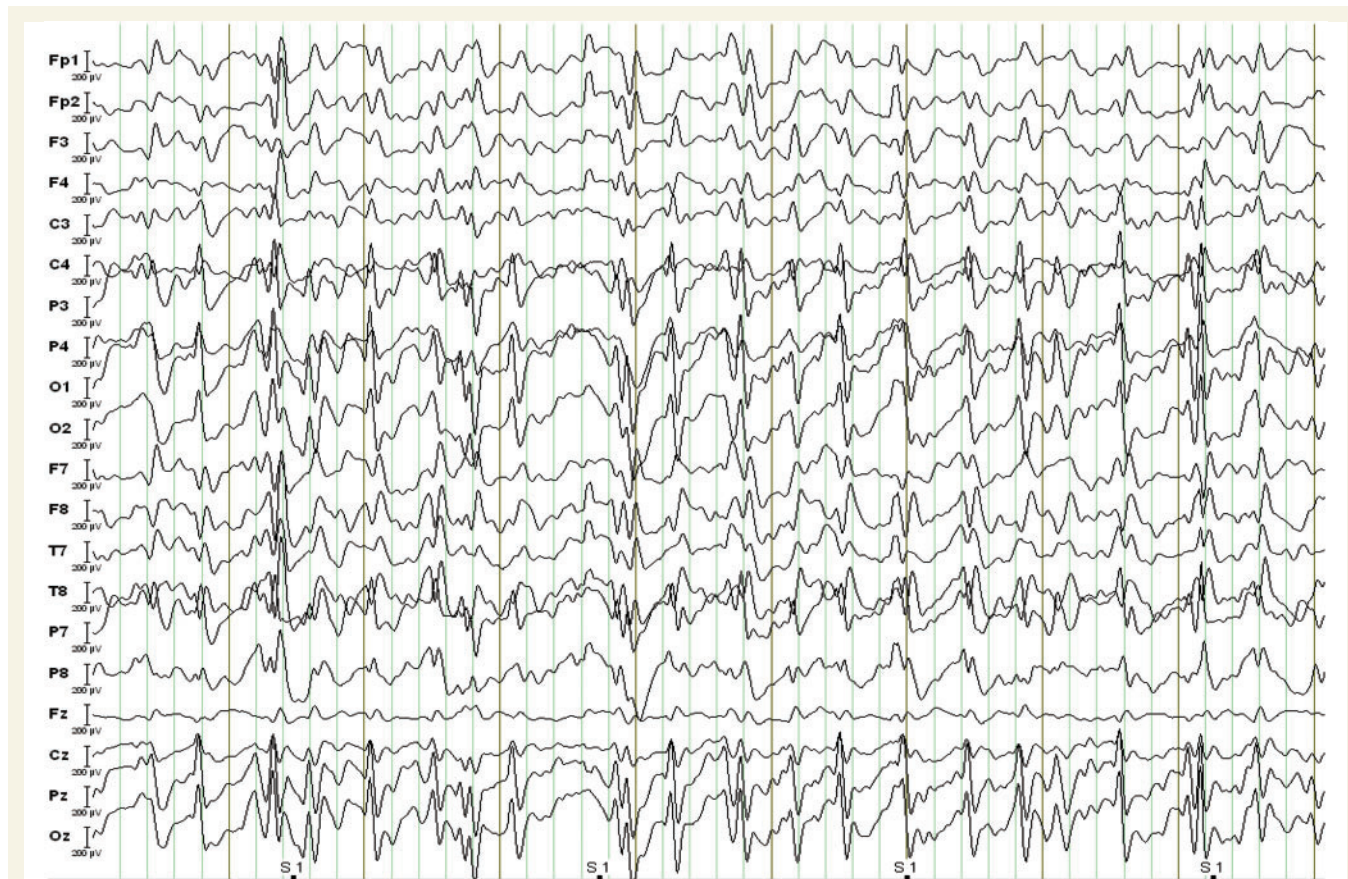

Figure 1 Typical pattern of spike-and-wave paroxysms in a patient with CSWS. The example represents the EEG obtained inside the scanner (original montage).

Table 1 Clinical and demographic characteristics of patients with CSWS and observed pathological activity on EEG during 20 min fMRI acquisition

Patient	Sex/age/age of epilepsy onset	Seizure type	MRI	Antiepileptic drugs	Neuropsychology	Number of spikes during fMRI
1	F/8/4	CPS, GTCS	–*	VPA	Aphasia, ADHD	1375
2	M/12/3	–	PVL	VPA	Global retardation	1656
3	M/9/3	SPS, GTCS	PVL	STM, VPA	Global retardation	1898
4	M/9/7	CPS, GTCS	Left HM	VPA, LTG	Aphasia, CD	1738
5	F/13/6	CPS, GTCS	–	VPA, LTG	Global retardation	1566
6	M/7/5	CPS	PVL	VPA, LEV	Global retardation	2308
7	F/10/4	CPS	–	VPA, TPM	Global retardation	2407
8	M/9/4	–	–	VPA	Aphasia, ADHD, CD	1398
9	F/5/2	–	PVL	Cortisone	Global retardation	1434
10	M/7/4	CPS, GTCS	–	VPA	Global retardation	1163
11	M/10/6	–	–	VPA	Autism	1315
12	M/3/1	CPS	PVL	LEV/TPM	Global retardation	1272

ADHD = attention deficit hyperactivity disorder; CD = conduct disorder; CPS = complex partial seizures; GTCS = generalized tonic-clonic seizures; HM = hippocampal mal-rotation; LEV = levetiracetam; LTG = lamotrigin; PVL = periventricular leucomalacia; SFS = simple focal seizures; STM = sulthiamine; TPM = topiramate; VPA = valproate. Age is given in years. SPIKE represent frequency in 20 min recording. * - negative MRI.

the Declaration of Helsinki and was approved by the local ethics committee. The parents gave written informed consent.

Data acquisition

The EEG was continuously recorded inside the MRI scanner from 32 scalp sites (10–20 system plus FC1, FC2, CP1, CP2, FC5, FC6, CP5, CP6, TP9, TP10, FT9, FT10) with a reference located between Fz and Cz. Sintered Ag/AgCl ring electrodes were attached using the 'BrainCap' (Falk-Minow Services, Herrsching-Breitbrunn, Germany), which is part of the magnetic resonance-compatible EEG recording system 'BrainAmp-MR' (Brainproducts Co., Munich, Germany). Electrode impedance was kept below $7\text{ k}\Omega$ (after subtraction of the value of the safety resistors). Data were transmitted from the high-input impedance amplifier (250-Hz low-pass filter, 10-s time constant, 16-bit resolution, dynamic range 16–38 mV) which was placed directly behind the head coil inside the scanner room and connected to a computer located outside the scanner room via a fibre optic cable. The scanner (10-MHz sampling rate) was synchronized with the EEG amplifier (5-kHz sampling rate). Online correction of gradient artefacts based on the averaged artefact subtraction algorithm was performed using RecView software (Brainproducts Co., Munich, Germany) enabling visual inspection of spikes throughout the recording.

BOLD-sensitive MRI was performed with a 3 Tesla MRI scanner (Philips Achieva, Philips, Best, The Netherlands) and a standard, 8-channel sensitivity encoding head coil. A single-shot T_2^* -weighted gradient-echo planar imaging sequence was used (repetition time = 2250 ms, echo time = 45 ms, 30 slices, 64×64 matrix, slice thickness = 3.5 mm, field of view = 200 mm, flip angle = 90°). Data from 540 brain volumes were acquired during the 20 min fMRI session. The first five images were discarded to ensure steady-state longitudinal magnetization. An anatomical MRI for superimposition with functional images was acquired using a T_1 -weighted three-dimensional (3D) multi planar reformatting sequence (1 mm slice thickness, 208×208 matrix, 150 slices, field of view = 208 mm, echo time = 3.6 ms, repetition time = 7.8 ms, flip angle = 8° , number of signal averages = 2).

EEG processing

Gradient artefacts as a result of electromagnetic distortion of the EEG through static and dynamic magnetic field during magnetic resonance data acquisition were removed offline using the averaged artefact subtraction method as implemented in the BrainVision Analyser 1.05 software (Brainproducts Co., Munich, Germany) (Allen *et al.* 1998, 2000). After artefact correction, the data were down-sampled to 250 Hz and filtered at 0.03–75 Hz. Heartbeat-related artefacts were reduced by means of the multiple source correction algorithm as implemented in Brain Electrical Source Analysis software BESA 5.2 (MEGIS Software Co., Munich, Germany) and described in Siniatchkin *et al.* (2007a). Epileptiform activity was identified semi-automatically using BESA, following the method of Bast *et al.* (2004). Firstly, the EEG was inspected to select a typical spike, showing similar morphology and topography to those marked on the EEG acquired outside the scanner (routine EEGs from the Northern German Epilepsy Centre). A spatiotemporal pattern-matching algorithm combined with visual inspection was then used to identify similar spikes throughout the recording (Scherg *et al.*, 1999, 2002). All spikes selected had similar shape and topography. The spike selection based on spike topography may enhance sensitivity of EEG-fMRI studies in epilepsy (Siniatchkin *et al.*, 2007a; Vulliemoz *et al.*, 2010). The quality of spike detection was confirmed by two experienced neurophysiologists independently, resulting in a consensus

concerning the spike set to be used for fMRI analysis and EEG source localization.

EEG source analysis

Following application of averaged artefact subtraction and multiple source correction methods, data quality was sufficient to allow reliable spike identification and electrical source imaging (Siniatchkin *et al.*, 2007a). Because spikes in patients with CSWS occurred in long sequences and bursts, one could suggest that spikes in the sequence may be related to propagated epileptic activity and the area of the initial activity (generator) of the spike within the sequence may be different than the area of initial activity of the first spike in the sequence (Ebersole *et al.*, 2000). Indeed, a preliminary analysis of all averaged spikes revealed a poor correspondence between electrical source imaging and fMRI results, especially for the initial epileptic activity. Therefore, for the purpose of electrical source imaging, we selected the first spike in every run of spikes preceded by a sufficiently long period of normal background (at least 2 s). The selected spikes were averaged and aligned to the global field power peak and processed in the epoch of ± 500 ms around this peak (Michel *et al.*, 2004a). As suggested by Ebersole (2000), we checked whether different voltage topographies appear over the course of the spike, indicating propagation. Two time frames were chosen to characterize spike topography: (i) from the beginning of the spike to the time point corresponding to 50% of the rising phase as an epoch characterizing a source of the possible spike generator: $t = t_{\text{spike_onset}}$ (see Scherg *et al.*, 1999; Huppertz *et al.*, 2001; Lantz *et al.*, 2003a); and (ii) an epoch around the peak of the spike: $t = t_{\text{spike_propagation}}$. The precise timings of the frames were local minima in the time course of the dissimilarity index, which is a measure inversely related to the spatial correlation between two scalp voltage map topographies: a minimum of dissimilarity therefore reflects a period of map stability (Lantz *et al.*, 2003a; Michel *et al.*, 2004b) (Figs 2, 3 and 4, parts C and D). Source analysis at $t = t_{\text{spike_onset}}$ and $t = t_{\text{spike_propagation}}$ was performed using a distributed linear inverse solution, based on a local autoregressive average model of the current density of the brain using the Cartool software (<http://brainmapping.unige.ch/Cartool.htm>), giving the two solutions: electrical source imaging-o and electrical source imaging-p, respectively (Grave de Peralta Menendez *et al.*, 2001; Michel *et al.*, 2004b). Validation and application of this localization method in epileptic EEG has been shown in previous studies (Brodbeck *et al.*, 2009, 2010; Groening *et al.*, 2009; Vulliemoz *et al.*, 2009, 2010b).

Local autoregressive average was calculated in a simplified realistic head model called SMAC (Spinelli *et al.*, 2000); the brain surface is extracted from the individual MRI and the best fitting sphere is estimated. Then the MRI is warped according to the ratio of the sphere radius and the real surface radius. Depending on brain size, between 3500 and 4500 solution points were defined in regular distances within the grey matter. The forward problem is then solved with an analytical solution using a realistic head model. Additional details can be found in Groening *et al.* (2009).

To assess the presence of population-wide effects, the results of the single-subject source analyses were then taken to a second level group analysis (Friston *et al.*, 1999). The results of the local autoregressive average source reconstruction were transformed to the standard Montreal Neurological Institute (MNI) space using Cartool and saved as a volume. The volumes were realigned, smoothed with the isotropic 9 mm Gaussian kernel and spatially normalized to the MNI template using SPM5 software (Statistical Parametric Mapping, Wellcome Department of Imaging Neurosciences, UCL, UK, <http://www.fil.ion>

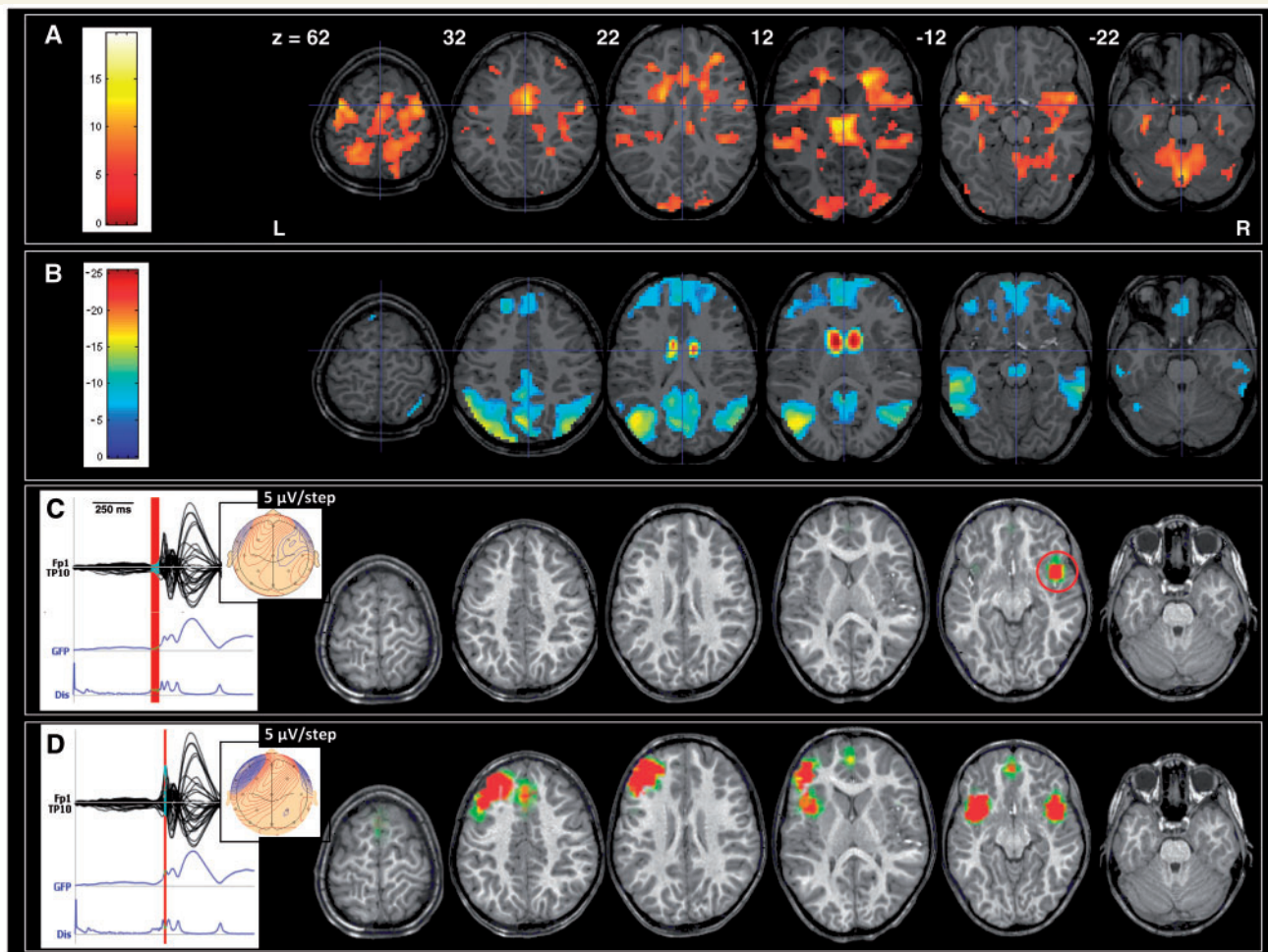


Figure 2 Patient 1: coregistered t -maps (canonical haemodynamic response function, family wise error correction for multiple voxel comparisons with $P < 0.05$) with positive (A) and negative BOLD signal changes (B). The first rising phase of the averaged spike and Global Field Power (GFP) is used for characterization of the initial epileptic activity (C). The propagated epileptic activity (D) was characterized at the time point of spike peak. This female suffered from Pseudo-Lennox syndrome and presented with drop attacks, atypical absences and secondary generalized tonic-clonic seizures. After normal development in the age of 7, she developed CSWS and additional neuropsychological deficits in the form of aphasia and attention-deficit with hyperactivity. After EEG-fMRI study, she was treated successfully with cortisone. Note that epileptic activity is generated in the right perisylvian cortex (red circle). The area of initial epileptic activity and the pattern of propagation correspond to the positive BOLD effect, especially in the perisylvian cortex. Moreover, the global maximum of haemodynamic change occurs in the thalamus pointing on the activity in the thalamocortical network associated with spike. Negative BOLD signal changes involve caudate nuclei and typical brain areas of the default mode network—precuneus, lateral parietal cortex and medial frontal cortex. Dis = dissimilarity.

.ucl.ac.uk/spm). With all patients, a random effect group analysis was performed.

Functional MRI processing

The fMRI data were analysed using SPM5. All volumes were realigned to the first volume and spatially normalized to the MNI template of the SPM software. Images were then smoothed using an isotropic Gaussian kernel of 6 mm and high-pass filtered at a cut-off of 128 s. The pre-processed fMRI time series were statistically analysed at an individual level using the General Linear Modelling approach, in which each spike was treated as a single event. Each event was represented as a stick function, convolved with a canonical haemodynamic

response function (peak at 6 s relative to onset, delay of undershoot = 16 s, length of kernel = 32 s) as implemented in SPM5 (Friston *et al.*, 1995). In each individual, one-tailed t -tests were applied to test for regional spike-related BOLD increases or decreases. At the voxel level, the significance level was set at $P < 0.05$ after correction for multiple comparisons across the whole brain using the family-wise error correction method as implemented in SPM5 (Friston *et al.*, 1995). This corresponded to t -values above 4.7. An extent threshold of five contiguous voxels was also applied. Individual statistical parametric t -maps were colour-coded and superimposed onto the individual coregistered T_1 -weighted images. Using the parameter estimates obtained by single-subject analyses, we performed a second-level random effect group analysis (one sample t -test) to test for

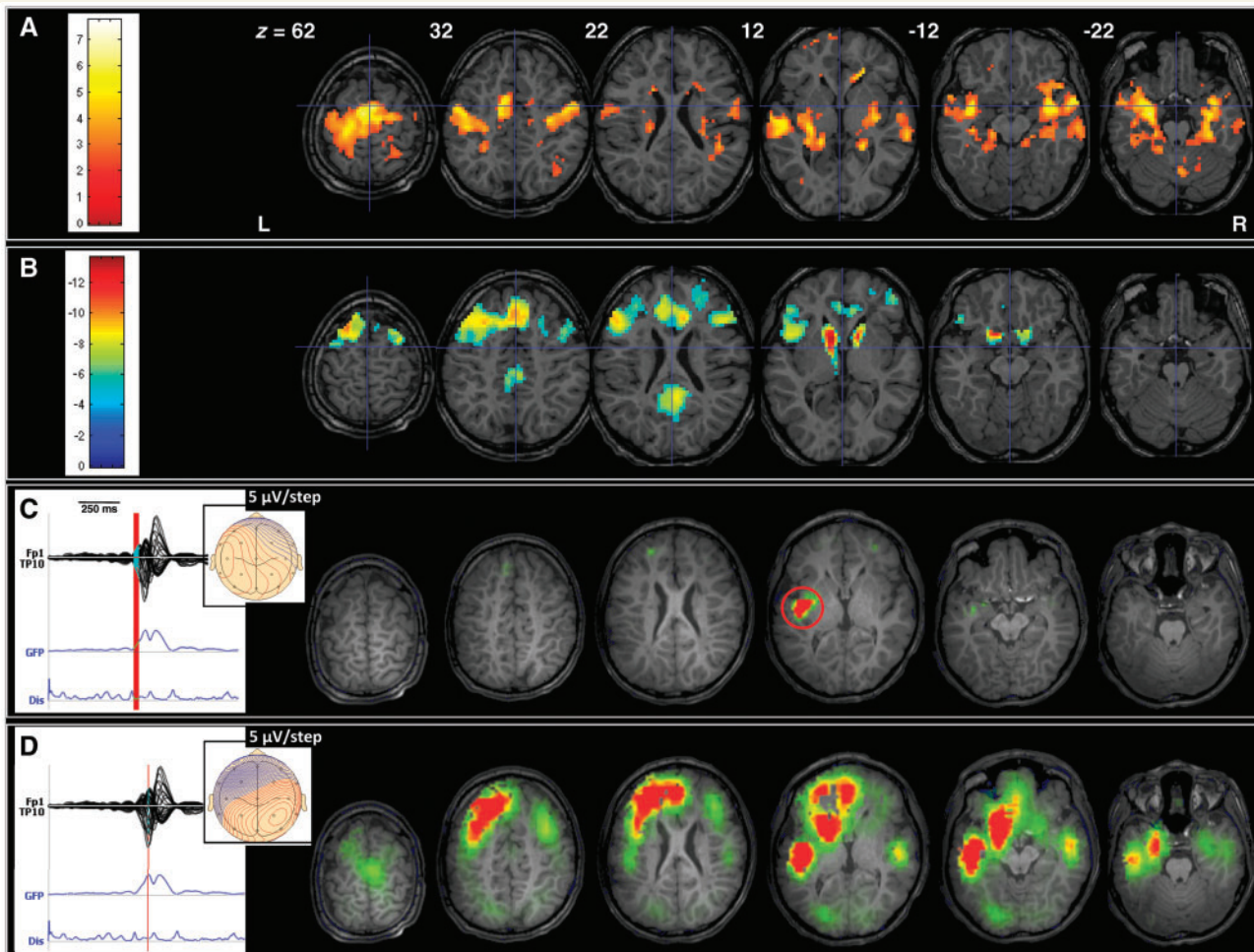


Figure 3 Patient 2: coregistered t -maps (canonical haemodynamic response function, family wise error corrected) with positive (A) and negative BOLD signal changes (B) as well as results of the EEG source analysis for the initial (C) and propagated (D) epileptic activity. This male patient was referred to the University Hospital of Paediatric Neurology because of developmental delay and autism following premature birth and perinatal cerebral infarction (MRI: extended periventricular leucomalacia). He never had epileptic seizures, always presented with focal epileptic activity in the routine EEGs and developed CSWS at the age of 12, which was successfully treated with cortisone after EEG-fMRI investigation. The initial epileptic activity occurs in the left perisylvian cortex and corresponds to positive BOLD signal changes. Spikes propagate bilaterally in both perisylvian and temporal regions. Note the involvement of the typical network of haemodynamic changes (positive BOLD effect) with bilateral activations in the perisylvian region, temporal, prefrontal and cingulate and temporal cortices. Negative BOLD signal changes were found in structures of the default mode network.

typical BOLD signal changes at the population level. The threshold was set at $P < 0.05$ (false discovery rate corrected). The resulting statistical maps were displayed in MNI space.

Results

EEG-functional MRI study

All patients demonstrated highly significant positive and negative spike-related BOLD signal changes ($P < 0.05$ corrected; Figs 2–4 and Table 2). Despite high spike frequency, the time series of BOLD responses were characterized by sufficient variability and visual comparison of the BOLD time series in the regions of significantly correlated change and EEG showed a good

correspondence with the epileptic spikes (Fig. 5). Maximal t -values varied between 5.9–19.7 for BOLD increases and between 4.7 and 25.4 for BOLD decreases. BOLD increases were observed bilaterally in the perisylvian region (insula, superior temporal gyrus, inferior frontal gyrus) and in the anterior cingulate gyrus/prefrontal cortex in all patients, the thalamus in five (42%), the temporal lobe in three (25%), the frontal cortex in five (42%) and in the parietal and occipital cortices in one (8%). BOLD decreases were revealed bilaterally in the parietal cortex in 11 patients (92%), in the precuneus in 10 (83%), in the medial prefrontal and frontal cortices in five (42%) and in the caudate nucleus in four (33%). The localization of maximal t -values for both positive and negative BOLD effects varied from patient to patient. No systematic difference in patterns was apparent between symptomatic and cryptogenic cases. The structural abnormalities found in six patients

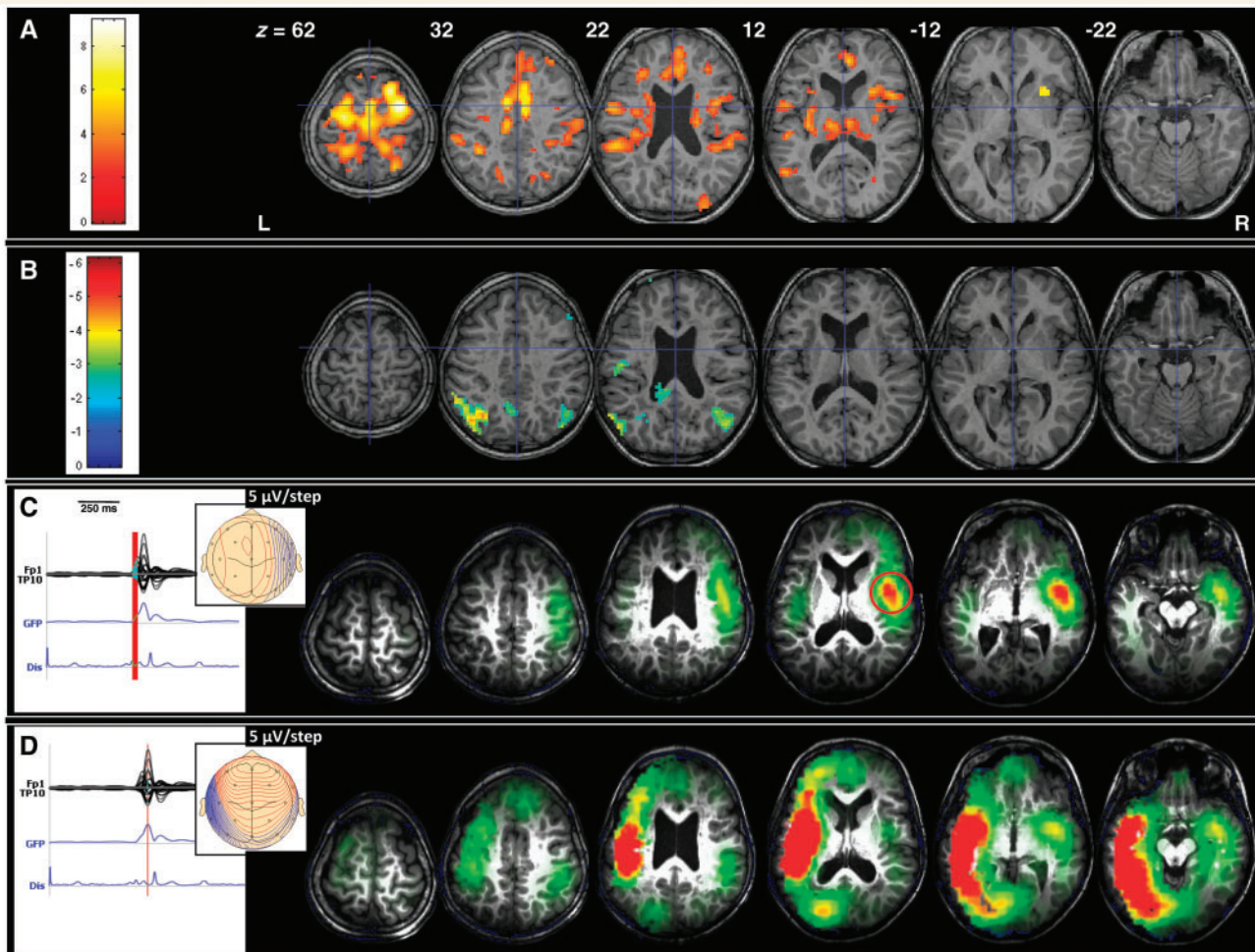


Figure 4 Patient 3: coregistered t -maps (canonical haemodynamic response function, family wise error corrected) with positive (A) and negative BOLD signal changes (B) as well as results of the EEG source analysis for the initial (C) and propagated (D) epileptic activity. Following perinatal complication (haemorrhage with periventricular leucomalacia on MRI), this male patient presented with global mental retardation and simple motor seizures, which tended to generalize into tonic-clonic seizures. At the age of 8, he developed CSWS and showed increase in seizure frequency. Note a good correspondence between the initial epileptic activity and positive BOLD signal changes in the right perisylvian region. The activity propagates into the other hemisphere and involves the left perisylvian area, temporal and parietal cortices. Negative BOLD signal changes can be found in the precuneus and parietal cortex.

(Table 1) did not correspond to any of the areas of significant BOLD signal change.

The group analysis revealed a significant bilateral positive BOLD effect in the perisylvian region, cingulate and prefrontal cortices and thalamus (Fig. 6 and Table 3), in a pattern resembling an arch. BOLD decreases were observed in the precuneus and bilaterally in the parietal cortex and in the caudate nucleus.

EEG source analysis

The results of the single-subject EEG source analysis were broadly similar across patients for both time points (Table 4). The initial epileptic activity was localized in the frontal cortex in three patients (25%), the perisylvian region/insula in eight (67%) and the parietal and occipital cortices in one (8%). A good correspondence between the initial epileptic activity as revealed by the EEG source

analysis and brain areas with regions of BOLD increase was found in 11 patients (92%). The epileptic activity propagated bilaterally in the perisylvian region in all patients, the frontal cortex in nine (75%), the posterior brain areas in eight (67%) and the temporal lobe in seven (58%). The source analysis for the propagation time point revealed source activity in the perisylvian region with corresponding spike-related BOLD increases in all patients. In six patients (50%), there was good correspondence between propagated source activity in the frontal and temporal cortices and regions of BOLD increase. Propagated source activity in the parietal cortex was in agreement with BOLD decreases in three patients (25%).

The group analysis of EEG source activity did not reveal any constant source for the rising phase of the spike, possibly because of different individual localization of the initial epileptic activity (Fig. 7A and Table 4). However, the group analysis of the

Table 2 Results of EEG-fMRI analyses for positive and negative CSWS-related BOLD effects

	BOLD increases					BOLD decreases						
	t-value	Perisylvian insula	Cingulate prefrontal	Temporal cortex	Thalamus	Frontal parietal	t-value	Precuneus	Parietal cortex	Medial prefrontal	Caudate nuclei	Occipital
1	19.69 (T)	+	+	+	+	+	25.39 (CN)	+	+	+	+	
2	7.74 (TC)	+	+	+		+	13.63 (CN)	+	+	+		
3	9.17 (CG)	+	+		+	+	6.14 (PC)	+				
4	10.58 (FC)	+	+			+	9.74 (FC)	+	+	+		
5	5.97 (PFC)	+	+				10.05 (OC)	+	+			+
6	10.97 (PC)	+	+			+	8.06 (PC)	+	+			+
7	5.95 (CG)	+	+		+		4.71 (PC)		+			
8	6.20 (In)	+	+		+		7.38 (FC)	+	+	+		+
9	6.83 (PFC)	+	+				7.14 (PC)	+	+			
10	7.95 (In)	+	+				6.42 (PC)	+	+			
11	6.81 (TC)	+	+	+			9.04 (OC)	+	+	+		+
12	10.30 (FC)	+	+		+	+	5.89 (PC)		+			

All *t*-values represent global maximum and are $P < 0.05$, corrected. In all patients, only bilateral changes were observed. In = insula; CG = cingulate gyrus; FC = frontal cortex; PC = parietal cortex; TC = temporal cortex; OC = occipital cortex; P = precuneus; T = thalamus; CN = caudate nucleus.

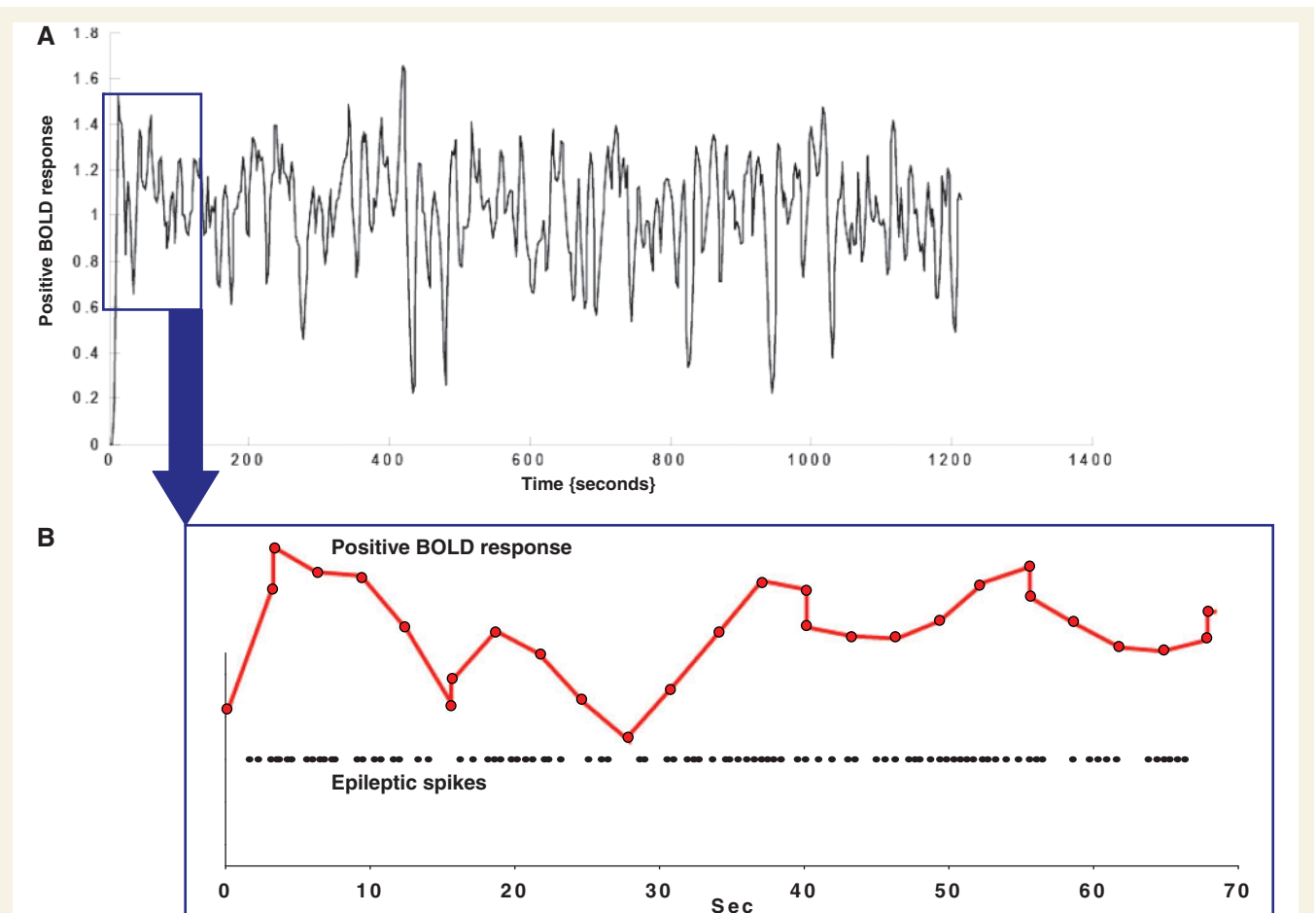


Figure 5 Positive BOLD response (A) that was obtained in Patient 1 in a voxel with the maximal *t*-value in the right insular region, which was chosen because of the correspondence between fMRI results and results of the electrical source imaging of the rising phase of the spike (beginning of epileptic activity). The first 70 s of recording are enlarged (B) to show the relation between variation of the fitted positive BOLD response and spike frequency. Note that frequent spikes were associated with an increase in BOLD response and gaps between spikes corresponded well with BOLD decreases. This good correlation between the occurrence of spikes and BOLD signal changes explains highly significant results of EEG-fMRI studies in patients with CSWS.

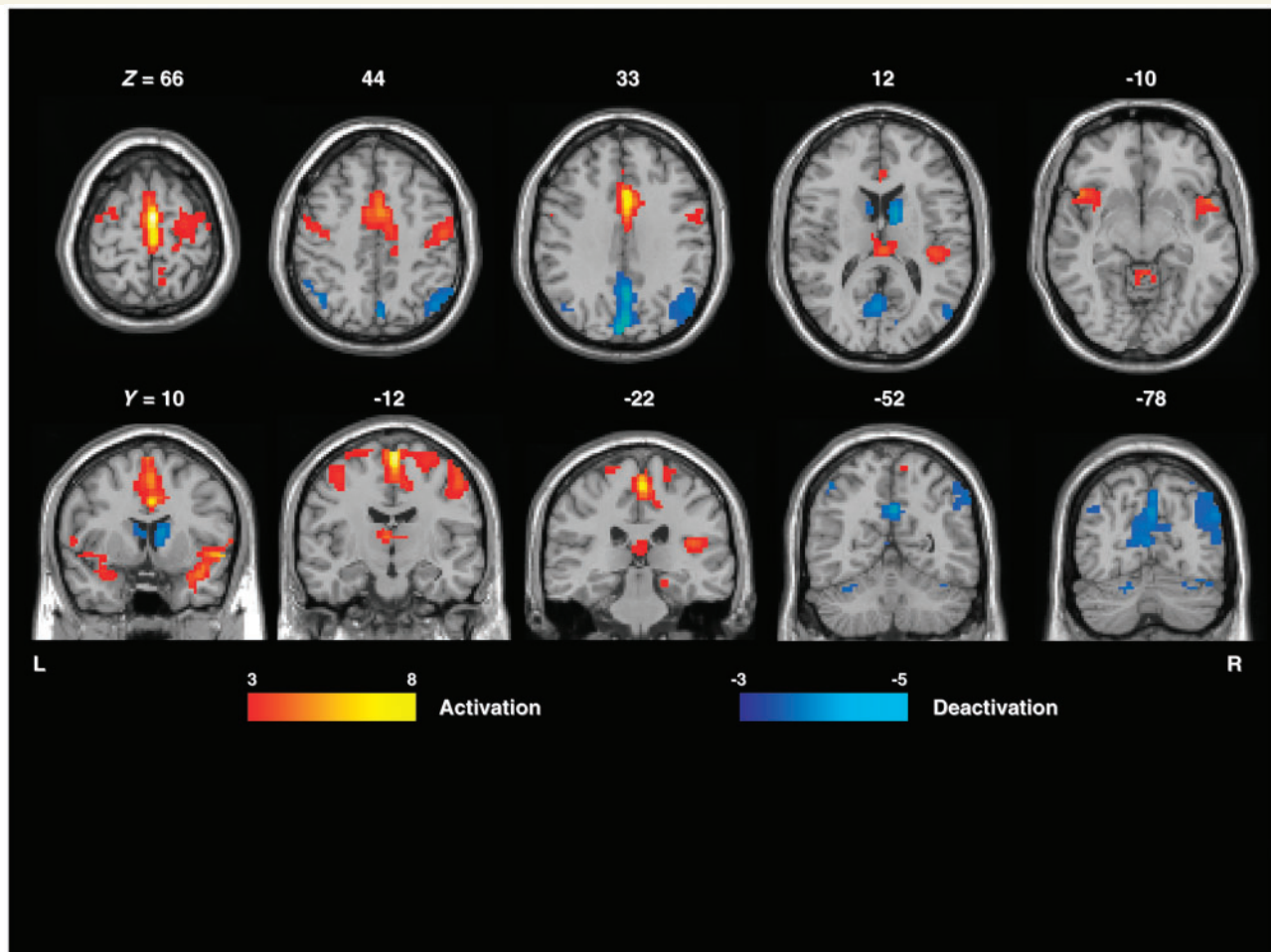


Figure 6 Results of the random effect group analysis for both positive and negative BOLD signal changes (false discovery rate corrected, $P < 0.05$).

Table 3 Results of the group analysis (maximum of activation in the cluster)

Structures	t-value	Voxels	MNI coordinates
BOLD increases			
Right perisylvian region and insula	7.27	293	36/0/−9
Left perisylvian region and insula	6.69	143	−51/−6/15
Right prefrontal cortex and cingulate gyrus	7.80	252	10/−9/51
Left prefrontal cortex and cingulate gyrus	6.19	154	−39/−15/54
Thalamus	4.11	54	12/−12/6
BOLD decreases			
Precuneus	4.40	271	5/−56/30
Right parietal cortex	4.40	364	51/−60/27
Left parietal cortex	4.54	117	−51/−69/30
Caudate nucleus	4.22	45	−8/15/5

propagated epileptic activity (peak) was able to describe electrical sources in the left and right perisylvian region, left and right temporal cortices (mostly in the superior temporal gyrus), temporo-parietal junction and the left prefrontal and parietal cortices.

The results of the source analysis on the group level show good correspondence with results of the random effect group analysis of fMRI data, especially with activation in the perisylvian region and deactivation in the parietal cortex and temporo-parietal junction. This positive correspondence between fMRI results and EEG pattern supports the contention that fMRI is able to reveal a physiologically meaningful pathological network.

Discussion

This study revealed the following main findings: (i) independent of aetiology, a common pattern of CSWS-related BOLD increases bilaterally in the perisylvian region; (ii) this pattern was confirmed using EEG source reconstruction showing a common bilateral pattern of propagation in the perisylvian region associated with different individual localization of the initial epileptic activity; (iii) there is frequent involvement of the prefrontal cortex and cingulate gyrus in both EEG-fMRI and source analysis; (iv) common BOLD increases in the thalamus and BOLD decreases in the caudate nuclei are associated with CSWS, especially revealed by the group analysis; and (v) there is a common pattern of BOLD decreases in the default mode network.

Table 4 Results of the EEG source analysis for the initial and propagated epileptic activity

Patient number	Spike number	Initial activity			Propagated activity			Correspond		
		Perisylvian insula	Frontal	Parietal occipital	Perisylvian insula	Cingulate prefrontal	Temporal	Frontal	Parietal occipital	Initial/propagated
1	54	R			B		B	B		+/+
2	24	L			B		L	B		+/+
3	88	R			B		L	L	L	+/+
4	91	L			B			B	B	+/+
5	43	L			B	B			B	+/+
6	47			B	B				B	+/+
7	26		L		B		L	L		+/+
8	70	L			B		B	B	B	+/+
9	56	L			B			B	R	+/+
10	23	L			B			B	B	+/+
11	45		L		B		R		B	-/+
12	29			L	B		B	B		+/+

L=left; R=right; B=bilateral. The last column shows correspondence between fMRI results and initial as well as propagated epileptic activity as revealed by the source analysis. The column 'Spike number' shows the number of spikes (first spike in the sequence with the EEG baseline of at least 2 s before the spike) that were averaged for the source analysis.

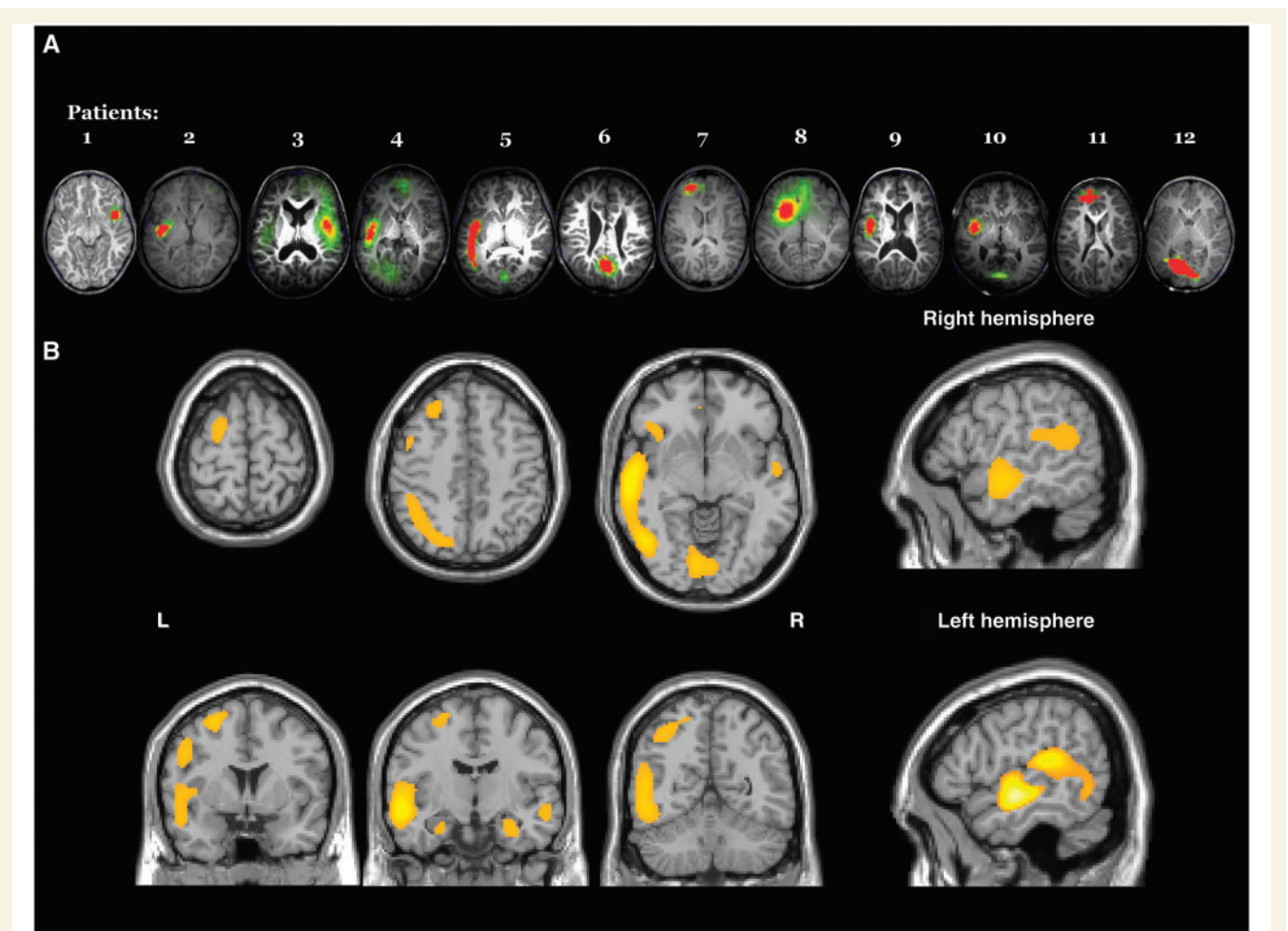


Figure 7 Results of the source analysis are presented for the initial epileptic activity on the individual level (A) and for the propagated epileptic activity on the group level (B).

Perisylvian network in CSWS

Our results support previous findings underlining the involvement of the perisylvian region during CSWS. The increased prevalence of CSWS in patients with the perisylvian polymicrogyria (Guerrini *et al.*, 1998) and sporadic association of structural abnormalities in the perisylvian region with Landau–Kleffner syndrome and CSWS (Solomon *et al.*, 1993; De Volder *et al.*, 1994; Tagawa *et al.*, 1999; Huppke *et al.*, 2005) provide clinical evidence to that effect. Consistent with our study, other authors have performed magnetoencephalography/EEG source analysis and have shown that the bilateral spikes generated in or propagate to the perisylvian cortex in many patients with Landau–Kleffner syndrome and CSWS (Morrell *et al.*, 1995; Paetau *et al.*, 1999; Sobel *et al.*, 2000; Paetau, 2009). Positron emission tomography (PET) and single-photon emission computed tomography studies have revealed brain areas of hypermetabolism and hypoperfusion in the perisylvian region and temporoparietal cortex associated with CSWS with and without Landau–Kleffner syndrome (Gaggero *et al.*, 1995; Maquet *et al.*, 1995; De Tiege *et al.*, 2004, 2008; Luat *et al.*, 2005). Morrell *et al.* (1995) investigated 14 children with Landau–Kleffner syndrome, showing CSWS in all but one. Although bilateral spikes were detected in all cases, the generator of epileptic activity was located unilaterally in the posterior speech cortex (Wernicke's area, the angular and supramarginal gyri). Patients with this unilateral generator underwent epilepsy surgery in the perisylvian region (multiple subpial transections) with substantial success: 50% of children had recovered age-appropriate speech and 29% improved their neuropsychological abilities, with cessation of CSWS in all cases. Surgical interventions in the perisylvian region have been performed in other studies showing a significant improvement in both EEG and neuropsychological performance (Irwin *et al.*, 2001; Cross and Nevill, 2009; Loddenkemper *et al.*, 2009; Paetau, 2009).

Although the perisylvian region seems to play an important role in the generation of spikes in the clinical tandem of Landau–Kleffner syndrome and CSWS (Solomon *et al.*, 1993; Da Silva *et al.*, 1997; Harbord *et al.*, 1999; Paetau *et al.*, 1999), in patients with CSWS without Landau–Kleffner syndrome the generator may be located in other cortical areas, and the epileptic activity seems to propagate bilaterally to the perisylvian cortex (Gaggero *et al.*, 1995; Maquet *et al.*, 1995; Morrell *et al.*, 1995; De Tiege *et al.*, 2004; Luat *et al.*, 2005). In most cases, the spikes propagate rapidly from one hemisphere to another, so that a focal origin to the spike with secondary bilateral synchrony may be suggested (Kobayashi *et al.*, 1994; Farnarier *et al.*, 1995; Paetau, 2009). Partial motor seizures that originate from different cortical regions (Tassinari *et al.*, 2005), focal EEG activity during both wakefulness and REM sleep (Galanopoulou *et al.*, 2000) and focal cortical areas with hypermetabolism and hypoperfusion individually distributed and well corresponding with the focus of spikes during wakefulness (Gaggero *et al.*, 1995; Maquet *et al.*, 1995) all provide evidence for individual cortical generators in CSWS. In our study, we described individual localization of the initial epileptic activity, which was detected in the perisylvian cortex in only four patients. Epileptic spikes propagated bilaterally to both perisylvian regions supporting the evidence for a secondary bilateral synchrony in

CSWS. It is worthwhile to mention that this specific pattern of propagation is identical in symptomatic and cryptogenic cases suggesting that the described bilateral synchrony in the perisylvian region is specific to CSWS rather than any aetiological factor.

The BOLD pattern (Fig. 3) shows an involvement of the prefrontal cortex and the cingulate gyrus. Interpreted in the light of the results of the source analysis, these BOLD responses are likely to represent areas of propagation. This complex pattern of propagation may explain complex neuropsychological deficits that often accompany CSWS. The perisylvian region is involved in acoustic perception and language development (Horwitz and Barun, 2004). The insular cortex and cingulate gyrus are important parts of neuronal networks of working memory, self-control, emotional processing and social cognition (Posner *et al.*, 2007; Rilling *et al.*, 2008; Behrens *et al.*, 2009). Functional abnormalities in these regions may explain the frequent association of CSWS with auditory agnosia, acquired aphasia, aggressiveness, attention-deficit hyperactivity and autistic features (Roulet Perez *et al.*, 1993; Galanopoulou *et al.*, 2000; Deonna and Roulet, 2006; Debiais *et al.*, 2007; Metz-Lutz, 2009). Involvement of the motor cortex in CSWS has been associated with motor impairment in form of dyspraxia, dystonia, ataxia or unilateral deficit (Veggiotti *et al.*, 1999; Galanopoulou *et al.*, 2000) and the appearance of negative myoclonus during wakefulness (Dalla Bernardina *et al.*, 1989). Propagated epileptic activity may disturb function in sensory and cognitive networks in the perisylvian, prefrontal and cingulate cortices and, in such a way, cause neuropsychological deficits (Halasz *et al.*, 2005). Moreover, epileptic spikes may interact with maturation of complex cognitive networks. Perisylvian, prefrontal and cingulate cortices undergo a long developmental process and are especially sensitive to environmental influences and intrinsic physiological perturbations throughout childhood and adolescence (Lenroot and Giedd, 2006; Marsh *et al.*, 2008). Considering consolidation of memory traces during sleep which involve similar cortical structures (Fischer *et al.*, 2005; Takashima *et al.*, 2009), spikes may interfere with the restructuring of cognitive networks in the sensitive phase of development. The reasons for propagation of CSWS to cortical structures that are characterized by a longest time frame of intensive synaptic pruning and ongoing progressive myelination of axons, remain to be understood. Our study, however, supports the concept of a link between CSWS and specific developmental abnormalities and residual neuropsychological deficits following successful treatment of this pathological condition (Tassinari *et al.*, 2005).

Involvement of thalamus and striatum in CSWS

A strong association of CSWS and slow sleep provide unequivocal arguments for involvement of the thalamocortical network (Halasz *et al.*, 2005). The majority of children with CSWS either do not have any epileptic activity or show well-localized focal spikes during both wakefulness and REM sleep. However, a pronounced synchronization with bilateral and generalized epileptic activity may be observed in the non-REM sleep (Galanopoulou *et al.*, 2000; Tassinari *et al.*, 2005; Nickels and Wirrell, 2008).

The work of the Steriade group systematically showed that non-REM sleep is characterized by the synchronous bursting-mode of the thalamocortical system, where spikes of the cortical neurons are highly synchronized, driven by the γ -aminobutyric acid (GABA)ergic gating machine of the thalamic reticular nucleus (Steriade, 2003; 2005). Synchronization of epileptiform spikes and slow oscillation during sleep may involve similar mechanisms. It seems likely that, during slow sleep, the cortex is prone to an abnormal synchronizing processes. A close relationship between sleep spindles and spike frequency and transformation of sleep K-complexes into epileptic paroxysmal depolarization shifts provide an argument for this hypothesis (Gloor *et al.*, 1990; Nobili *et al.*, 1999; Steriade, 2005). In man, primary and secondary generalized paroxysms, as well as bilateral epileptic activity in both generalized and partial epilepsies, have been associated with a strong activation of the thalamus suggesting an involvement of the thalamocortical network in processes of broad pathological synchronization (Aghakhani *et al.*, 2004, 2006; Gotman *et al.*, 2005; Hamandi *et al.*, 2006; Moeller *et al.*, 2008a, b). Moreover, highly synchronous epileptic activity during sleep is commonly accompanied by thalamic activation (Moeller *et al.*, 2008b). We showed that bilateral and generalized epileptic activity in CSWS is commonly associated with a significant activation in the thalamus, as revealed by the group analysis. The prominent role of the thalamus in CSWS has been supported by studies demonstrating that thalamic injuries may cause CSWS (Guzzetta *et al.*, 2005; Kelemen *et al.*, 2006). Taking into account close and rich connections between the thalamus and perisylvian/premotor cortex (Ojermann, 1984; Horwitz and Braun, 2004), it can be assumed that sleep-related increases in pathological thalamic activity may contribute to facilitated synchronization in CSWS and to the described pattern of spike propagation.

Moreover, this study provided evidence for the involvement of the caudate nucleus in CSWS. BOLD decreases in the striatum have been repeatedly found in patients with generalized spike and wave discharges (Gotman *et al.*, 2005; Hamandi *et al.*, 2006; Moeller *et al.*, 2008a, b). The studies on generalized paroxysms have hypothesized that the decrease in the BOLD signal may reflect a reduced corticostriatal drive during epileptic activity, since the caudate nuclei receive strong continuous cortical input from associative areas. Another explanation may be provided by the results from recent studies on rats with idiopathic epileptiform activity which suggested that the basal ganglia act as a remote control system for epileptic spikes. During paroxysms, the cortico-thalamo-palidal network shows rhythmic bursting, whereas striatal output neurons are silenced (Slaght *et al.*, 2004; Paz *et al.*, 2005). It was suggested that the acute drop in firing rate of striatal neurons results from a feed-forward synaptic inhibition, which may contribute to processes of termination of epileptiform activity (Paz *et al.*, 2005, 2007). The decrease in striatal neuronal activity during epileptiform discharges in rats may correspond to the BOLD decreases observed here.

Default mode network in CSWS

The first EEG-fMRI study on CSWS was published by De Tiege *et al.* (2007). The authors investigated a 9-year-old girl suffering

from partial seizures and who developed CSWS and neuropsychological deficits. Epileptiform activity was associated with focal activations in the right superior frontal, postcentral and superior temporal cortices as well as deactivations in the lateral and medial frontoparietal cortices, posterior cingulate gyrus and cerebellum, in line with our results. BOLD decreases in the precuneus, retrosplenial cortex, parietal and anterior medial frontal cortices were consistently found in all our patients and in the case investigated by De Tiege *et al.* (2007). These structures are usually involved in a pattern of deactivation that occurs during the initiation of task-related activity and represent default mode network that is active in the resting brain with a high degree of functional connectivity (Raichle *et al.*, 2001). It has been suggested that the default mode network constitutes a necessary favourable neurometabolic environment for cognitive functions, represents a physiological baseline for processes of attention and working memory and supports dynamical integration of cognitive and emotional processing (Raichle and Mintun, 2006). Abnormal activity in the default mode network and disturbed connectivity between the structures involved may influence task performance and contribute to the pathogenesis of neuropsychiatric disorders such as attention-deficit hyperactivity, Alzheimer's disease, autism, schizophrenia and depression (Eichele *et al.*, 2008; Broyd *et al.*, 2009). Moreover, altered activity in the default mode network has been associated with fluctuations and disturbance of consciousness (Boly *et al.*, 2008).

It has been suggested that disruption of the resting state activity by pathological processes (e.g. those that give rise to spike) may be related to alterations in cognitive function and this may be the possible mechanism that underlies cognitive deficits in epilepsy (Gotman *et al.*, 2005). Deactivations in the default mode network have been described in awake patients with primary and secondary generalized paroxysms and absence seizures (Aghakhani *et al.*, 2004; Gotman *et al.*, 2005; Hamandi *et al.*, 2006; Laufs *et al.*, 2006; Moeller *et al.*, 2008a, b). These default mode network deactivations may reflect disturbance of awareness or consciousness associated with absences (Laufs *et al.*, 2006; Moeller *et al.*, 2008a). Moreover, in patients suffering from temporal lobe epilepsy, Laufs *et al.* (2007) found spike associated deactivation of the default mode network, particularly in precuneus and left and right parietal lobes. The authors argue that the transient cognitive impairments and performance deficits observed in temporal lobe epilepsy may be associated with dysfunction of the default mode network.

However, it is important to note that fMRI studies based on correlation analyses such as those mentioned above cannot shed light on the causal relationships between EEG (taken either as purely electrical events or markers of cognitive states) and BOLD patterns. In this regard, models of effective connectivity can be used to study the causal relationships at the neural level from fMRI data such as Dynamic Causal Modelling (Friston *et al.*, 2003). Application of this approach on fMRI acquired during GSW has shown that the state of the precuneus may act as a modulator of the onset (and offset) of the pathological activity (Vaudano *et al.*, 2009). As noted by the authors, this finding relates specifically to the onset of the discharges and does not preclude a reversed causal link between the pathological activity and

deactivation in the default mode network. For example, there could be reinforcement of the default mode network deactivation during sustained discharges, leading to neuropsychological effects.

A prominent pattern of activity in the default mode network has been observed during sleep and has been associated with processes of anatomical connectivity between the frontal and parietal cortical regions that are necessary for memory consolidation and information processing during sleep (Dang Vu *et al.*, 2008; Horowitz *et al.*, 2009). In our previous study, we demonstrated significant deactivations in the default mode network associated with generalized spike-and-wave discharges in sedated sleeping patients (Moeller *et al.*, 2008*b*). We suggest that spikes in patients with CSWS may interrupt activity in the default mode network and in such a way intervene with cognitive processes during sleep. Arguments for this suggestion were provided by De Tiege *et al.* (2008); using longitudinal PET scans acquired before and after successful treatment of CSWS, the authors demonstrated common resolution of default mode network hypometabolism associated with recovery. The authors hypothesized that the neurophysiological effects associated with CSWS activity are not restricted to the epileptic focus but spread to connected brain areas via a possible mechanism of surrounding and remote inhibition (Witte and Bruehl, 1999). Our study supports this hypothesis demonstrating spike-associated deactivation in the default mode network independently on the individual focus of epileptic activity.

Limitations of the study

In this study, very frequent epileptic activity was analysed. It could be suggested that the frequent events may violate assumptions of the general linear model and reduce fMRI sensitivity (Jacobs *et al.*, 2008). However, although the epileptic syndrome investigated here is defined as continuous spikes and waves, the spikes do not occur with absolute temporal regularity (Tassinari *et al.*, 2005). Figure 5 shows a good correspondence between periods of increased spiking rate and BOLD amplitude. Highly significant results of individual fMRI analyses and good correspondence between results of fMRI study and EEG source reconstruction support the validity of the approach used. However, the influence of spike frequency on fMRI results may not be completely excluded. In view of the results of the group analysis, the lack of significant BOLD signal changes in the thalamus and caudate nucleus observed in five and four patients, respectively, can be explained by a combination of conservative threshold level and relatively weak effect in those cases. The number of electrodes used in the current study (30 scalp sites), difficulties in identifying the rising phase of the spikes and the intrinsic limitations of local autoregressive average algorithm as an assumption-based inverse solution are known limitations of the source analysis strategy used here (Lantz *et al.*, 2003*b*; Michel *et al.*, 2004). Moreover, we used a simplified realistic head model to solve the forward problem analytically, instead of using more exact (and more complex) numerical methods such as the 'finite element method' or the 'boundary element method' (Ding *et al.*, 2007). The simplified method applied here offers an easy and fast extraction of the head model and a fast and accurate analytical solution to the forward problem, at the expense of perhaps being less precise.

Nevertheless, accurate source localization using this head model has been demonstrated in different clinical and experimental studies in the past (Lantz *et al.*, 2003*a*; Michel *et al.*, 2004; Phillips *et al.*, 2005; Sperli *et al.*, 2006). Our study raises issues of interpretation related to the possible effects of sleep-inducing drugs on the relationship between sleep and BOLD, the difficulty of sleep staging and defining a baseline due to the high level of epileptic activity. A number of studies have demonstrated a direct link between sleep depth, level of resting state activity and connectivity in the default mode network and BOLD (Moehring *et al.*, 2008; Horowitz *et al.*, 2009). Furthermore, deactivation in the default mode network may be a product of interaction between epileptic spikes and network providing functional connectivity between anterior and posterior brain regions without any relation to physiological rest (Morcom and Fletcher, 2007). As noted previously the negative BOLD signal changes in the default mode network seem to be non-specific to CSWS (Aghakhani *et al.*, 2004; Gotman *et al.*, 2005; Hamandi *et al.*, 2006; Laufs *et al.*, 2006; Moeller *et al.*, 2008*a, b*). Whatever the mechanism, the relation between CSWS, memory consolidation and fluctuations of activity in the default mode network has to be investigated in more detail in the future.

Conclusions

Independent of aetiology and individual area of initial epileptic activity, patients with CSWS were characterized by a consistent specific neuronal network of propagation. The activation in the perisylvian/prefrontal network was associated with both activation in the thalamocortical network and deactivation in the default mode network. Since these networks seem prominent in neuropsychological processes and consolidation of memory traces during sleep, a possible influence of epileptic spikes on these networks may explain neuropsychological deficits and developmental abnormalities in CSWS. However, studies are needed that directly investigate information processing during sleep in relation to epileptic activity.

Acknowledgements

MS, JM and RB were supported by the German Research Foundation (Deutsche Forschungsgemeinschaft DFG, grant SI 1419/2-1). RR and LL acknowledge the financial support of the Medical Research Council (MRC grant G0301067) and that this work was undertaken at UCLH/UCL who received a proportion of funding from the UK Department of Health's NIHR Biomedical Research Centres funding scheme. The Cartool software (<http://brainmapping.unige.ch/Cartool.htm>) has been programmed by Denis Brunet and is supported by the Centre for Biomedical Imaging (CIBM) of Geneva and Lausanne, Switzerland.

References

Aghakhani Y, Bagshaw AP, Benar CG, Hawco C, Andermann F, Dubeau F, Gotman J. fMRI activation during spike and wave spikes in idiopathic generalized epilepsy. *Brain* 2004; 127: 1127–44.

- Aghakhani Y, Kobayashi E, Bagshaw AP, Hawco C, Benar CG, Dubeau F, et al. Cortical and thalamic fMRI responses in partial epilepsy with focal and bilateral synchronous spikes. *Clin Neurophysiol* 2006; 117: 177–91.
- Allen PJ, Josephs O, Turner R. A method for removing imaging artifact from continuous EEG recorded during functional MRI. *NeuroImage* 2000; 12: 230–39.
- Allen PJ, Polizzi G, Krakow K, Fish DR, Lemieux L. Identification of EEG events in the MR scanner: the problem of pulse artifact and a method for its subtraction. *NeuroImage* 1998; 8: 229–39.
- Bast T, Oezkan O, Rona S, Stippich C, Seitz A, Rupp A, et al. EEG and MEG source analysis of single and averaged interictal spikes reveals intrinsic epileptogenicity in focal cortical dysplasia. *Epilepsia* 2004; 45: 621–31.
- Behrens TE, Hunt LT, Rushworth MF. The computation of social behavior. *Science* 2009; 324: 1160–4.
- Boly M, Phillips C, Tshibanda L, Vanhaudenhuyse A, Schabus M, Dang-Vu TT, et al. Intrinsic brain activity in altered states of consciousness: how conscious is the default mode of brain function. *Ann NY Acad Sci* 2008; 1129: 119–29.
- Boor R, Jacobs J, Hinzmann A, Bauermann T, Scherg M, Boor S, et al. Combined spike-related functional MRI and multiple source analysis in the non-invasive spike localization of benign rolandic epilepsy. *Clin Neurophysiol* 2007; 118: 901–9.
- Brodbeck V, Spinelli L, Lascano AM, Pollo C, Schaller K, Vargas MI, et al. Electrical source imaging for presurgical focus localization in epilepsy patients with normal MRI. *Epilepsia* 2010; 51: 583–91.
- Brodbeck V, Lascano AM, Spinelli L, Seeck M, Michel CM. Accuracy of EEG source imaging of epileptic spikes in patients with large brain lesions. *Clin Neurophysiol* 2009; 120: 679–85.
- Broyd SJ, Demanuele C, Debener S, Helps SK, James CJ, Sonuga-Barke EJS. Default-mode brain dysfunction in mental disorders: a systematic review. *Neurosci Biobehav Rev* 2009; 33: 279–96.
- Commission on Classification and Terminology of the International League Against Epilepsy: Proposal for revised classification of epilepsies and epileptic syndromes. *Epilepsia* 1989; 30: 383–99.
- Cross JH, Neville GR. The surgical treatment of Landau-Kleffner syndrome. *Epilepsia* 2009; 50 (Suppl 7): 63–7.
- Dalla Bernardina B, Fontana E, Michelizza B, Colamaria V, Capovilla G, Tassinari CA. Partial epilepsies in childhood, bilateral synchronization, continuous spike-waves during slow sleep. In: Manelis S, Bental E, Loeber JN, Dreifuss FE, editors. *Advances in epileptology*. NY: Raven Press; 1989. p. 295–302.
- Dang-Vu TT, Schabus M, Desseilles M, Albouy G, Boly M, Darsaud A, et al. Spontaneous neural activity during human slow wave sleep. *Proc Natl Acad Sci USA* 2008; 105: 15160–5.
- Da Silva EA, Chugani DC, Muzik O, Chugani HT. Landau-Kleffner syndrome: Metabolic abnormalities in temporal lobe are a common feature. *J Child Neurol* 1997; 12: 489–95.
- Debiais S, Tuller L, Barthez MA, Monjauze C, Khamsi A, Praline J, et al. Epilepsy and language development: the continuous spike-waves during slow sleep syndrome. *Epilepsia* 2007; 48: 1104–10.
- Deonna T, Roulet E. Autistic spectrum disorder: evaluating a possible contributing or causal role of epilepsy. *Epilepsia* 2006; 47 (Suppl 2): 79–82.
- De Tiege X, Goldman S, Laureys S, Verheulpen D, Chiron C, Wetzberger C, et al. Regional cerebral glucose metabolism in epilepsies with continuous spikes and waves during sleep. *Neurology* 2004; 63: 853–57.
- De Tiege X, Harrison S, Laufs H, Boyd SG, Clark CA, Allen P, et al. Impact of interictal epileptic activity on normal brain function in epileptic encephalopathy: an electroencephalography – functional magnetic resonance imaging study. *Epilepsy Behav* 2007; 11: 460–65.
- De Tiege X, Ligt N, Goldman S, Poznanski N, de Saint Martin A, van Bogaert P. Metabolic evidence for remote inhibition in epilepsies with continuous spike-waves during sleep. *NeuroImage* 2008; 40: 802–10.
- De Volder AG, Michel C, Thauvoy C, Willems G, Ferriere G. Brain glucose utilisation in acquired childhood aphasia associated with a sylvian arachnoid cyst: recovery after shunting as demonstrated by PET. *J Neurol Neurosurg Psychiatry* 1994; 57: 296–300.
- Ding L, Worrell GA, Lagerlund TD, He B. Ictal source analysis: localization and imaging of causal interactions in humans. *NeuroImage* 2007; 34: 575–86.
- Ebersole JS. Noninvasive localization of epileptogenic foci by EEG source modeling. *Epilepsia* 2000; 41: 24–33.
- Eichele T, Debener S, Calhoun VD, Specht K, Engel AK, Hugdahl K, et al. Prediction of human errors by maladaptive changes in event-related brain networks. *Proc Natl Acad Sci USA* 2008; 105: 6173–8.
- Eriksson K, Kylläinen A, Hirvonen K, Nieminen P, Koivikko M. Visual agnosia in a child with non-lesional occipito-temporal CSWS. *Brain Dev* 2003; 25: 262–7.
- Farnarier G, Kouna P, Genton P. Amplitude EEG mapping in three cases of CSWS. In: Beaumanoir A, Bureau M, Deonna T, editors. *Continuous spike and wave during slow sleep, electrical status epilepticus during slow wave sleep: acquired epileptic aphasia and related conditions*. London: John Libbey; 1995. p. 91–8.
- Fischer S, Nitschke MF, Melchert UH, Erdmann C, Born J. Motor memory consolidation in sleep shapes more effective neuronal representations. *J Neurosci* 2005; 25: 11248–55.
- Friston KJ, Holmes AP, Worsley KP, Poline JB, Frith C, Frackowiak RSJ. Statistical parametric maps in functional imaging: a general linear approach. *Hum Brain Mapp* 1995; 2: 189–210.
- Friston KJ, Holmes AP, Price CJ, Büchel C, Worsley KJ. Multisubject fMRI studies and conjunction analyses. *NeuroImage* 1999; 10: 385–96.
- Friston KJ, Harrison L, Penny W. Dynamic causal modelling. *NeuroImage* 2003; 19: 1273–1302.
- Gaggero R, Caputo M, Fiorio P, Pessagno A, Baglietto MG, Muttini P, et al. SPECT and epilepsy with continuous spike waves during slow-wave sleep. *Child's Nerv Syst* 1995; 11: 154–60.
- Galanopoulou AS, Bojko A, Lado F, Moshe SL. The spectrum of neuropsychiatric abnormalities associated with electrical status epilepticus in sleep. *Brain Dev* 2000; 22: 279–95.
- Gloor P, Avoli M, Kostopoulos G. Thalamocortical relationships in generalized epilepsy with bilaterally synchronous spike and wave spike. In: Avoli M, Gloor P, Kostopoulos G, Naquet R, editors. *Generalized epilepsy: neurobiological approaches*. MA: Birkhauser, Boston; 1990. p. 190–212.
- Gotman J, Grova C, Bagshaw A, Kobayashi E, Aghakhani Y, Dubeau F. Generalized epileptic spikes show thalamocortical activation and suspension of the default state of the brain. *Proc Natl Acad Sci USA* 2005; 102: 15236–40.
- Gotman J, Kobayashi E, Bagshaw AP, Bénar CG, Dubeau F. Combining EEG and fMRI: a multimodal tool for epilepsy research. *J Magn Reson Imaging* 2006; 23: 906–20.
- Grave de Peralta Menendez JM, Gonzalez Andino S. Noninvasive localization of electromagnetic epileptic activity. I. Method descriptions and simulations. *Brain Topogr* 2001; 14: 131–7.
- Groening K, Brodbeck V, Moeller F, Wolff S, van Baalen A, Michel CM, et al. Combination of EEG-fMRI and EEG source analysis improves interpretation of spike-associated activation networks in paediatric pharmacoresistant focal epilepsy. *NeuroImage* 2009; 46: 827–33.
- Grova C, Daunizeau J, Kobayashi E, Bagshaw AP, Lina JM, Dubeau F, et al. Concordance between distributed EEG source localization and simultaneous EEG-fMRI studies of epileptic spikes. *NeuroImage* 2008; 39: 75574.
- Guerrini R, Genton P, Bureau M, Parmeggiani A, Salas-Puig X, Santucci M. Multilobar polymicrogyria, intractable drop attack seizures, and sleep-related electrical status epilepticus. *Neurology* 1998; 51: 504–12.
- Guzzetta F, BatVeredice C, Donvito V, Pane M, Lettori D, Chricozzi F, et al. Early thalamic injury associated with epilepsy and continuous spike-wave during slow sleep. *Epilepsia* 2005; 46: 889–900.
- Halasz P, Kelemen A, Clemens B, Saracz J, Rosdy B, Rasonyi G, et al. The perisylvian epileptic network. An unifying concept. *Ideggyogy Sz* 2005; 58: 21–31.

- Hamandi K, Salek-Haddadi A, Fish DR, Lemieux L. EEG/functional MRI in epilepsy: the Queen Square experience. *J Clin Neurophysiol* 2004; 21: 241–8.
- Hamandi K, Salek-Haddadi A, Laufs H, Liston A, Friston K, Fish DR, et al. EEG-fMRI of idiopathic and secondary generalized epilepsies. *NeuroImage* 2006; 31: 1700–10.
- Harbord MG, Singh R, Morony S. SPECT abnormalities in Landau-Kleffner syndrome. *J Clin Neurosci* 1999; 6: 9–16.
- Holmes GL, Lenck-Santini PJ. Role of interictal epileptiform abnormalities in cognitive impairment. *Epilepsy Behav* 2006; 8: 504–15.
- Horowitz SG, Braun AR, Carr WS, Picchioni D, Balkin TJ, Fukunaga M, et al. Decoupling of the brain's default mode network during deep sleep. *Proc Natl Acad Sci USA* 2009; 106: 11376–81.
- Horwitz B, Braun AR. Brain network interactions in auditory, visual and linguistic processing. *Brain Lang* 2004; 89: 377–84.
- Huppertz HJ, Hof E, Klisch J, Wagner M, Lucking CH, Kristeva-Feige R. Localization of interictal delta and epileptiform EEG activity associated with focal epileptogenic brain lesions. *NeuroImage* 2001; 13: 15–28.
- Huppke P, Kallenberg K, Gärtner J. Perisylvian polymicrogyria in Landau-Kleffner syndrome. *Neurology* 2005; 64: 1660.
- Irwin K, Birch V, Lees J, Polke C, Alarcon G, Binnie C, et al. Multiple subdural transaction in Landau-Kleffner syndrome. *Dev Med Child Neurol* 2001; 43: 248–52.
- Jacobs J, Kobayashi E, Boor R, Muhle H, Wolff S, Hawco C, et al. Hemodynamic responses to interictal epileptiform discharges in children with symptomatic epilepsy. *Epilepsia* 2007; 48: 2068–78.
- Jacobs J, Hawco C, Kobayashi E, Boor R, LeVan P, Stephani U, et al. Variability of the hemodynamic response as a function of age and frequency of epileptic spike in children with epilepsy. *NeuroImage* 2008; 40: 601–14.
- Jacobs J, Levan P, Moeller F, Boor R, Stephani U, Gotman J, et al. Hemodynamic changes preceding the interictal EEG spike in patients with focal epilepsy investigated using simultaneous EEG-fMRI. *NeuroImage* 2009; 45: 1220–31.
- Kelemen A, Barsi P, Gyorsok Z, Sarac J, Szucs A, Halasz P. Thalamic lesion and epilepsy with generalized seizures, ESES and spike-wave paroxysms – report of three cases. *Seizure* 2006; 15: 454–8.
- Kobayashi K, Nishibayashi N, Ohtsuka Y, Oka E, Ohtahara S. Epilepsy with electrical status epilepticus during slow sleep and secondary bilateral synchrony. *Epilepsia* 1994; 35: 1097–103.
- Kobayashi E, Bagshaw AP, Benar CG, Aghakhani Y, Andermann F, Dubeau F, et al. Temporal and extratemporal BOLD responses to temporal lobe interictal spikes. *Epilepsia* 2006; 47: 343–54.
- Lantz G, Spinelli L, Seeck M, de Peralta Menendez RG, Sottas CC, Michel CM. Propagation of interictal epileptiform activity can lead to erroneous source localizations: a 128-channel EEG mapping study. *J Clin Neurophysiol* 2003a; 20: 311–9.
- Laufs H, Lengler U, Hamandi K, Kleinschmidt A, Krakow K. Linking generalized spike-and-wave spikes and resting state brain activity by using EEG/gMTI in a patient with absence seizures. *Epilepsia* 2006; 47: 444–8.
- Laufs H, Duncan JS. Electroencephalography/functional MRI in human epilepsy: what it currently can and cannot do. *Curr Opin Neurol* 2007; 20: 417–23.
- Laufs H, Hamandi K, Salek-Haddadi A, Kleinschmidt AK, Duncan JS, Lemieux L. Temporal lobe interictal epileptic spikes affect cerebral activity in “default mode” brain regions. *Hum Brain Mapp* 2007; 28: 1023–32.
- Lenroot R, Giedd JN. Brain development in children and adolescents: Insights from anatomical magnetic resonance imaging. *Neurosci Biobehav Rev* 2006; 30: 718–29.
- Loddenkemper T, Cosmo G, Kotagal P, Haut J, Klaas P, Gupta A, et al. Epilepsy surgery in children with electrical status epilepticus in sleep. *Neurosurgery* 2009; 64: 328–37.
- Luat AF, Asano E, Juhasz C, Chandana SR, Shah A, Sood S, et al. Relationship between brain glucose metabolism positron emission tomography (PET) and electroencephalography (EEG) in children with continuous spike-and-wave activity during slow-wave sleep. *J Child Neurol* 2005; 20: 682–90.
- Marsh R, Gerber AJ, Peterson BS. Neuroimaging studies of normal brain development and their relevance for understanding childhood neuropsychiatric disorders. *J Am Acad Child Adolesc Psychiatry* 2008; 47: 1233–51.
- Maquet P, Hirsch E, Metz-Lutz MN, Motte J, Dive D, Marescaux C, et al. Regional cerebral glucose metabolism in children with deterioration of one or more cognitive functions and continuous spike-and-wave spikes during sleep. *Brain* 1995; 118: 1497–520.
- Metz-Lutz MN. The assessment of auditory function in CSWS: lessons from long-term outcome. *Epilepsia* 2009; 50 (Suppl 7): 73–6.
- Michel CM, Lantz G, Spinelli L, Grave de Peralta R, Landis T, Seeck M. 128-channel EEG source imaging in epilepsy: clinical yield and localization precision. *J Clin Neurophysiol* 2004a; 21: 71–83.
- Michel CM, Murray MM, Lantz G, Gonzalez S, Spinelli L, Grave de Peralta R. EEG source imaging. *Clin Neurophysiol* 2004b; 115: 2195–222.
- Moehring J, Moeller F, Jacobs J, Wolff S, Boor R, Jansen O, et al. Non-REM sleep influences results of fMRI studies in epilepsy. *Neurosci Lett* 2008; 443: 61–6.
- Moeller F, Siebner H, Wolff S, Muhle H, Boor R, Granert O, et al. EEG-fMRI in children with untreated childhood absence epilepsy. *Epilepsia* 2008a; 49: 1510–9.
- Moeller F, Siebner HR, Wolff S, Muhle H, Boor R, Granert O, et al. Changes in activity of striato-thalamo-cortical network precede generalized spike wave discharges. *NeuroImage* 2008b; 39: 1839–49.
- Morcom AM, Fletcher PC. Does the brain have a baseline? Why we should be resisting a rest. *NeuroImage* 2007; 37: 1073–1082.
- Morrell F, Whisler WW, Smith MC, Hoepfner TJ, de Toledo-Morrell L, Pierre-Louis SJC, et al. Landau-Kleffner syndrome: treatment with subpial intracortical transection. *Brain* 1995; 118: 1529–46.
- Neilson LA, Kovalyov M, Koles ZJ. A computationally efficient method for accurately solving the EEG forward problem in a finely discretized head model. *Clin Neurophysiol* 2005; 116: 2302–14.
- Nickels K, Wirrell E. Electrical status epilepticus in sleep. *Semin Pediatr Neurol* 2008; 15: 50–60.
- Nobili L, Ferrillo F, Baglietto N. Relationship of sleep interictal epileptiform spikes to sigma activity (12–16 Hz) in benign epilepsy of childhood with rolandic spikes. *Clin Neurophysiol* 1999; 110: 39–46.
- Ojermann GA. Common cortical and thalamic mechanisms for language and motor functions. *Am J Physiol* 1984; 246: 901–3.
- Paetau R, Granstrom ML, Blomstedt G, Jousmäki V, Korkman M, Liukkonen E. Magnetencephalography in presurgical evaluation of children with the Landau-Kleffner syndrome. *Epilepsia* 1999; 40: 326–35.
- Paetau R. Magnetoencephalography in Landau-Kleffner syndrome. *Epilepsia* 2009; 50 (Suppl 7): 51–4.
- Patry G, Lyagoubi S, Tassinari CA. Subclinical “electrical status epilepticus” induced by sleep in children. *Arch Neurol* 1971; 24: 242–52.
- Paz JT, Deniau JM, Charpier S. Rhythmic bursting in the cortico-subthalamic-pallidal network during spontaneous genetically determined spike and wave discharges. *J Neurosci* 2005; 25: 2092–101.
- Paz JT, Chavez M, Saillet S, Deniau JM, Charpier S. Activity of ventral thalamic neurons during absence seizures and modulation of cortical paroxysms by the nigrothalamic pathway. *J Neurosci* 2007; 27: 929–41.
- Phillips C, Mattout J, Rugg MD, Maquet P, Friston K. An empirical Bayesian solution to the source reconstruction problem in EEG. *Neuroimage* 2005; 24: 997–1011.
- Posner MI, Rothbart MK, Sheese BE, Tang Y. The anterior cingulate gyrus and the mechanism of self-regulation. *Cogn Affect Behav Neurosci* 2007; 7: 391–5.
- Raichle ME, MacLeod AM, Snyder AZ, Powers WJ, Gusnard DA, Shulman GL. A default mode of brain function. *Proc Natl Acad Sci USA* 2001; 98: 676–82.

- Raichle ME, Mintun MA. Brain work and brain imaging. *Ann Rev Neurosci* 2006; 29: 449–76.
- Rilling JK, King-Casas B, Sanfey AG. The neurobiology of social decision-making. *Curr Opin Neurobiol* 2008; 18: 159–65.
- Roulet Perez E, Davidoff V, Despland PA, Deonna T. Mental and behavioral deterioration of children with epilepsy and CSWS: acquired epileptic frontal syndrome. *Dev Med Child Neurol* 1993; 35: 661–74.
- Schafir Y, Prensky AL. Acquired epileptiform opercular syndrome: a second case report, review of the literature, and comparison to the Landau-Kleffner syndrome. *Epilepsia* 1995; 36: 1050–7.
- Scherg M, Bast T, Berg P. Multiple source analysis of interictal spikes: goals, requirements, and clinical value. *J Clin Neurophysiol* 1999; 16: 214–24.
- Scherg M, Ille N, Bornfleth H. Advanced tools for digital EEG review: virtual source montages, whole-head mapping, correlation and phase analysis. *J Clin Neurophysiol* 2002; 19: 91–112.
- Scholtes FBJ, Hendriks MPH, Renier WO. Cognitive deterioration and electrical status epilepticus during slow sleep. *Epilepsy Behav* 2005; 6: 167–73.
- Siniatchkin M, Moeller F, Jacobs J, Stephani U, Boor R, Wolff S, et al. Spatial filters and automated spike detection based on brain topographies improve sensitivity of EEG-fMRI studies in focal epilepsy. *Neuroimage* 2007; 37: 834–43.
- Siniatchkin M, van Baalen A, Jacobs J, Moeller F, Moehring J, Boor R, et al. Different neuronal networks are associated with spikes and slow activity in hypsarrhythmia. *Epilepsia* 2007; 48: 2312–21.
- Slaght SJ, Paz T, Chavez M, Deniau JM, Mahon S, Charpier S. On the activity of the corticostriatal networks during spike-and-wave discharges in a genetic model of absence epilepsy. *J Neurosci* 2004; 24: 6816–25.
- Sobel DF, Aung M, Otsubo H, Smith MC. Magnetoencephalography in children with Landau-Kleffner syndrome and acquired epileptic aphasia. *Am J Neuroradiol* 2000; 21: 301–07.
- Solomon GE, Carson D, Pavlakis S, Fraser R, Labar D. Intercranial EEG monitoring in Landau-Kleffner syndrome associated with left temporal lobe astrocytoma. *Epilepsia* 1993; 34: 557–60.
- Sperli F, Spinelli L, Seeck M, Kurian M, Michel CM, Lantz G. EEG source imaging in pediatric epilepsy surgery: A new perspective in presurgical workup. *Epilepsia* 2006; 47: 981–90.
- Spinelli L, Gonzalez Andoni S, Lantz G, Michel CM. Electromagnetic inverse solutions in anatomically constrained spherical head models. *Brain Topogr* 2000; 13: 115–25.
- Steriade M. Neuronal substrates of sleep and epilepsy. Cambridge (UK): Cambridge University Press; 2003. p. 522.
- Steriade M. Sleep, epilepsy and thalamic reticular inhibitory neurons. *Trends Neurosci* 2005; 28: 317–24.
- Tagawa T, Itagaki Y, Kobayashi M, Sano T, Sumi K. Nonconvulsive status epilepticus in a child with congenital bilateral perisylvian syndrome. *Pediatr Neurol* 1999; 21: 579–82.
- Takashima A, Nieuwenhuis ILC, Jensen O, Talamini LM, Rijpkema M, Fernandez G. Shift from hippocampal to neocortical centered retrieval network with consolidation. *J Neurosci* 2009; 29: 10087–93.
- Tassinari CA, Rubboli G, Volpi L, Billard C, Bureau M. Electrical status epilepticus during slow sleep (ESES or CSWS) including acquired epileptic aphasia (Landau-Kleffner syndrome). In: Rodger J, Bureau M, Dravet C, Genton P, Tassinari CA, Wolf P, editors. *Epileptic syndromes in infancy, childhood and adolescence*. 4th edn. Montrouge: John Libbey Eurotext Ltd; 2005. p. 295–314.
- Veggiotti P, Beccaria F, Guerrini R, Capovilla G, Lanzi G. Continuous spike-and-wave activity during slow-wave sleep: syndrome or EEG pattern? *Epilepsia* 1999; 40: 1593–601.
- Vaudano AE, Laufs H, Kiebel SJ, Carmichael DW, Hamandi K, Guye M, et al. Causal hierarchy within the thalamo-cortical network in spike and wave spikes. *PloS One* 2009; 4: e6475.
- Vulliemoz S, Thornton R, Rodionov R, Carmichael DW, Guye M, Lhatoo S, et al. The spatio-temporal mapping of epileptic networks: combination of EEG-fMRI and EEG source imaging. *NeuroImage* 2009; 46: 834–43.
- Vulliemoz S, Lemieux L, Daunizeau J, Michel CM, Duncan JS. The combination of EEG source imaging and EEG-correlated functional MRI to map epileptic networks. *Epilepsia* 2010a; 51: 491–505.
- Vulliemoz S, Rodionov R, Carmichael DW, Thornton R, Guye M, Lhatoo SD, et al. Continuous EEG source imaging enhances analysis of EEG-fMRI in focal epilepsy. *NeuroImage* 2010; 49: 3219–29.
- Witte OW, Bruehl C. Distant functional and metabolic disturbances in focal epilepsy. *Adv Neurol* 1999; 81: 383–88.