

# Increased anterior corpus callosum size associated positively with hypnotizability and the ability to control pain

James E. Horton,<sup>1,2</sup> Helen J. Crawford,<sup>2</sup> Gregory Harrington<sup>3</sup> and J. Hunter Downs III<sup>4</sup>

<sup>1</sup>Department of Social and Behavioral Sciences, The University of Virginia's College at Wise, Wise,

<sup>2</sup>Department of Psychology, Virginia Polytechnic Institute and State University, Blacksburg, VA, <sup>3</sup>Department of Radiology, University of California at Davis, Sacramento, CA and <sup>4</sup>Department of Psychiatric Medicine, University of Virginia, Charlottesville, VA, USA

Correspondence to: James E. Horton, Department of Social and Behavioral Sciences, The University of Virginia's College at Wise, 1 College Avenue, Wise, VA 24293-4412, USA

E-mail: jhorton@uvawise.edu or hjc@vt.edu

## Summary

This is the first MRI study to report differences in brain structure size between low and highly hypnotizable, healthy, right-handed young adults. Participants were stringently screened for hypnotic susceptibility with two standardized scales, and then exposed to hypnotic analgesia training to control cold pressor pain. Only the highly hypnotizable subjects (HHs) who eliminated pain perception were included in the present study. These HHs, who demonstrated more effective attentional and inhibitory

capabilities, had a significantly ( $P < 0.003$ ) larger (31.8%) rostrum, a corpus callosum area involved in the allocation of attention and transfer of information between prefrontal cortices, than low hypnotizable subjects (LHs). These results provide support to the neuropsychophysiological model that HHs have more effective frontal attentional systems implementing control, monitoring performance and inhibiting unwanted stimuli from conscious awareness, than LHs.

**Keywords:** attention; corpus callosum; hypnotic analgesia; pain; rostrum

**Abbreviations:** AC-PC = anterior commissure–posterior commissure; ADHD = attention deficit hyperactivity disorder; FOV = field of view; fMRI = functional MRI; HHs = highly hypnotizable subjects; LHs = low hypnotizable subjects; MPRAGE = magnetization prepared rapid acquisition gradient echo; PFC = prefrontal cortices; rCBF = regional cerebral blood flow; ROI = region of interest

Received December 7, 2003. Revised March 17, 2004. Accepted March 19, 2004. Advanced Access publication July 1, 2004

## Introduction

The corpus callosum, the main fibre tract connecting the cerebral hemispheres, plays a pivotal role in establishing communication about sensory integration, inhibition and attentional processing between corresponding homologous areas of the two hemispheres (Banich, 1998; for a review see Zaidel and Iacoboni, 2003). Of particular relevance to the present study, fibres of the rostrum and genu in the anterior corpus callosum serve as the bridge between different areas of the prefrontal cortices (PFC) (Pandya and Seltzer, 1986; Tan *et al.*, 1991). As pointed out by Braun *et al.* (2003) (p. 245), the PFC is 'densely packed with callosal neurons' (Karol and Pandya, 1971; Van Essen *et al.*, 1982). These fibres are involved in the

interhemispheric transfer of information and executive processing undertaken by the frontal cortex (Witelson, 1985; Clarke *et al.*, 1989; Gazzaniga, 1995; Rueckert and Levy, 1996). Overall, the PFC is involved in monitoring and controlling information processing. The dorsolateral PFC is mainly involved in goal-directed executive control that is either excitatory or inhibitory, cognitive flexibility, monitoring performance and incoming signals, and determining what sensory information reaching the cortex may or may not reach consciousness, whereas the orbitofrontal cortex is proposed to be primarily involved in executive control of emotional responses initiated by other brain regions (Posner and DiGirolamo, 1998; Gehring

and Knight, 2000; Rule *et al.*, 2002; Stuss and Knight, 2002) and decision making (Manes *et al.*, 2002). As noted elsewhere, there is 'powerful evidence that the PFC provides a net inhibitory regulation of early sensory transmission' (Stuss and Knight, 2002; p. 581) at subcortical (Edinger *et al.*, 1975) and cortical (Alexander *et al.*, 1976; Skinner and Yingling, 1977; Yingling and Skinner, 1977) regions. The PFC is involved with sensory gating or filtering of irrelevant stimuli, and thereby reduces interference with higher cognitive processes (Boutros and Belger, 1999; Knight *et al.*, 1999; Staines *et al.*, 2002). Individuals with prefrontal insult or deficits demonstrate significantly less sustained attention and sensory gating abilities than healthy controls (Braff and Geyer, 1990; Yamaguchi and Knight, 1990; Judd *et al.*, 1992; Chao and Knight, 1995; Knight *et al.*, 1999).

Theoretical models (Cook, 1986; Banich, 1995; Chiarello, 1995) propose that effective interhemispheric inhibition and/or transfer of information via the anterior corpus callosum would be correlated with increased axon number or larger diameter axons (Aboitiz, 1992; Aboitiz *et al.*, 2003). Furthermore, callosal size may be related to interhemispheric transfer time (Jancke and Steinmetz, 1994), resulting in more effective sensory integration and gating. In support, structural neuroimaging studies of individuals with attention deficit hyperactivity disorder (ADHD), thought to arise from a developmental deficit in brain circuitry that underlies inhibitory processing, found them to have decreased anterior corpus callosum regional size in children (Hynd *et al.*, 1991; Giedd *et al.*, 1994, 2001; Baumgardner *et al.*, 1996; Mataro *et al.*, 1997) and left orbito-frontal volume reductions in adults (Hesslinger *et al.*, 2002). The present study compared the corpus callosum morphology of highly hypnotizable individuals (HHs), who had previously demonstrated inhibitory control abilities, including the complete elimination of the perceptions of pain and distress from conscious awareness to experimental pain, with low hypnotizable individuals (LHs), who did not have these abilities.

Numerous studies have demonstrated that HHs appear to have a more effective frontal attentional control system than do LHs (for reviews, see Crawford and Gruzelier, 1992; Crawford, 1994; Crawford *et al.*, 1999; Gruzelier, 1999). Suggestive of greater neural effectiveness, HHs typically demonstrate faster reaction times during complex decision-making tasks (Acosta and Crawford, 1985; Mészáros *et al.*, 1989; Crawford *et al.*, 1995) and shorter latencies for certain components of auditory, visual and somatosensory evoked potentials than other less hypnotizable subjects (De Pascalis, 1994; Crawford *et al.*, 1998b; Nordby *et al.*, 1999). Furthermore, HHs often display greater EEG hemispheric asymmetries and hemispheric specificity for tasks than LHs (MacLeod-Morgan and Lack, 1982; Mészáros *et al.*, 1989; Crawford, 1990; Sabourin *et al.*, 1990; Crawford *et al.*, 1996).

The cognitive inhibition of pain, both experimental and clinical, can be learned particularly by those individuals who are highly hypnotizable (Hilgard and Hilgard, 1994). This is because they have excellent sensory and perceptual gating abilities and are able to reallocate attentional resources and

inhibit unwanted stimuli from reaching perceptual awareness (Crawford and Gruzelier, 1992; Hilgard and Hilgard, 1994; Crawford, 1994). Hypnotic analgesia is thought to involve an active inhibitory process of supervisory, executive control by the anterior frontal cortex interacting with and modulating other parts of the brain (for a review see Crawford, 1994; for an alternative view, see Miller and Bowers, 1993), as evidenced in functional MRI (fMRI) (Crawford *et al.*, 1998a, 2000), PET (Rainville *et al.*, 1997, 1999, 2002; Wik *et al.*, 1999), regional cerebral blood flow (rCBF) (Crawford *et al.*, 1993) and electrophysiological (De Pascalis and Perrone, 1996; Kropotov *et al.*, 1997; Crawford *et al.*, 1998c, 1999) studies.

These considerations led us to postulate that, within a population of healthy young adults without known ADHD or learning disabilities, HHs with demonstrated inhibitory control abilities would have a significantly larger anterior corpus callosum than LHs.

## Material and methods

### Participants

Our participants, healthy university students aged 18–29 years, previously participated in an fMRI investigation of pain in conditions of attend and hypnotic analgesia (Crawford *et al.*, 1998a, 2000). Participants were eight HHs (four men) who could eliminate all distress and perception of sensory pain to experimentally produced pain (cold pressor pain; electrical stimulation), and 10 LHs (five men) who could not. Participants were strongly right-handed (Annett, 1970), reported no use of tobacco, no past chronic pain episodes, no contra-indication for MRI scans (e.g. floating metallic bodies, claustrophobia for small spaces), no significant medical illness, and no known diagnosis of psychiatric disorders, learning disabilities or attentional (including ADHD) disorders. At the time of the MRI, they were medication-free (except birth control pills for some of the women), caffeine-free for at least 12 h and alcohol-free for at least 48 h. They reported no depression [Beck Depression Inventory (Beck *et al.*, 1961): LHs,  $0.80 \pm 0.93$ ; HHs,  $0.88 \pm 1.13$ ]. Of the original 20 participants, one was excluded during scanning due to claustrophobia and one was excluded due to morphological irregularities. The subjects' consent was obtained according to the Declaration of Helsinki, and approval was granted by the Institutional Review Boards of the University of Virginia and Virginia Polytechnic Institute and State University. Participants received monetary compensation for participation.

### Hypnosis screening

Eligible participants were screened, following an established approach (Crawford, *et al.*, 1993, 1998c; Hilgard and Hilgard, 1994). First, they were administered two well known, standardized measures of hypnotic susceptibility, the Harvard Group Scale of Hypnotic Susceptibility (Shor and Orne, 1962) and the Stanford Hypnotic Susceptibility Scale, Form C (Weitzenhoffer and Hilgard, 1962). To continue, participants had to score consistently high (9–12) or low (0–4) in hypnotic susceptibility, be strongly right-handed, and self-report excellent health and no history of concussion or other medical history that might interfere with neurophysiological processing. They then were trained to eliminate perception of pain and distress with standardized hypnotic analgesia suggestions to cold pressor pain

(Crawford, *et al.*, 1993, 1998c; Hilgard and Hilgard, 1994). Only HHs who eliminated pain and distress perception were accepted into the fMRI study. LHs were unable to reduce pain significantly.

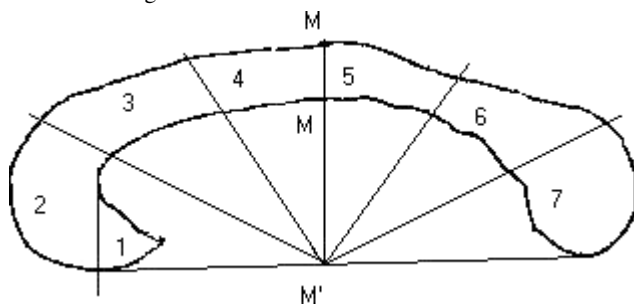
### MRI acquisition

Anatomical MRI images were recorded, as part of an fMRI study of pain and hypnotic analgesia (Crawford *et al.*, 1998a, 2000). The anatomical MRI was acquired at the University of Virginia Medical School using a 1.5 Tesla Siemens Vision scanner (Siemens Medical Solutions, Malvern, PA, USA) with the magnetization prepared rapid acquisition gradient echo (MPRAGE) protocol to acquire 3D T1-weighted images with a field of view (FOV) of 256 mm. It included a sequence of 128 sagittal images taken perpendicular to the anterior commissure–posterior commissure (AC-PC) line. Image slices were 1.8-mm thick with an in-plane resolution of  $1.1 \times 1.1$  mm that extended from the most superior aspect through the most inferior aspect of the brain.

### Image analyses

Images were processed and measured by one investigator (J.H.), who was blind to participant's hypnotic level and sex. Anatomical images were imported into AFNI software (Cox, 1996) and prepared for analyses. To correct the image for undesirable effects of head tilt, pitch and rotation, images were realigned to the same sagittal, horizontal and coronal planes by anterior and posterior commissure with rotation around the AC-PC axis corrected by realigning with the interhemispheric fissure. Based upon a common approach to area measurement and subsequent analyses (Bigler, 1996; Downs *et al.*, 1999), images were spatially normalized and transformed into Talairach standardized space (Talairach and Tournoux, 1998) to compensate for individual differences in overall brain size and thereby more accurately reflect actual differences in structure size.

Two images from each hemisphere were selected at 1-mm intervals located 2 and 3 mm from the sagittal midline for measurement and analyses; they did not differ significantly in size from one another within each hemisphere. Area measurements of delineated corpus callosum sections were obtained using Scion Image software (Scion Corporation). A geometric division was used to maintain consistency in corpus callosum section delineation across participants. The corpus callosum sections were identified and divided based on the radial method of division used by Clarke *et al.* (1989), with an additional division of the rostrum based on the straight-line method used by Witelson (1985). This yielded seven regions of interest shown in Fig. 1.



**Fig. 1** Delineation of the corpus callosum. Delineated sections: (1) rostrum; (2) genu; (3) rostral body; (4) anterior mid-body; (5) posterior mid-body; (6) isthmus; and (7) splenium. Divisions 2–7 are based on the radial method used by Clarke *et al.* (1989), with an additional division of the rostrum (1) based on the straight-line method used by Witelson (1985).

The corpus callosum radial division was based on the centre point, identified as the mid-point between the most anterior point of the genu and the most posterior point of the splenium, and determined by pixel count of the image. The resulting corpus callosum mid-point was transferred to a baseline located inferior to the corpus callosum and drawn across the most inferior points of the genu and rostrum at the anterior corpus callosum portion, and the most inferior point of the splenium at the posterior corpus callosum portion. The corpus callosum mid-point was transferred to the baseline by a vertical line from the mid-point (M) to its intersection with the baseline at an angle of  $90^\circ$  (M'). Radial lines at intervals of  $30^\circ$  and  $60^\circ$  were drawn from the relocated mid-point on the baseline to intersect the anterior and posterior portions. The rostrum was delineated by a perpendicular line located at the most posterior point of the curve of the genu just inferior to the rostral body and extending from the curve of the genu inferior through the rostrum and intersecting the baseline at an angle of  $90^\circ$ .

The corpus callosum regions of interest (ROI) were outlined, and accumulated surface area determined using summed pixels within each ROI. For each corpus callosum region, a total area was independently obtained on three occasions and an average determined.

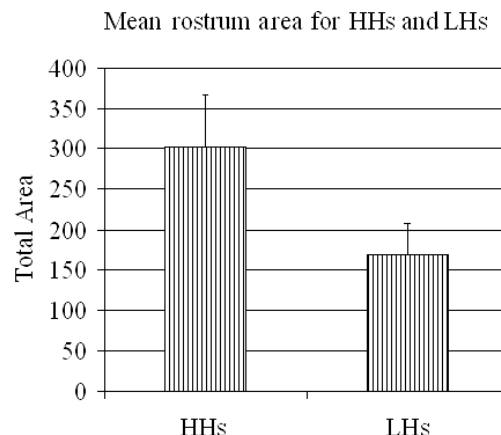
### Inter- and intrarater reliability of the corpus callosum measurement

To assess intrarater reliability, the primary researcher (J.H.), who was unaware of group or gender identification, collected three independent measures of each ROI and the total callosal area. The reliability of corpus callosum measurements was excellent, with an intraclass correlation coefficient for the total callosal area of 0.987 and intraclass correlation coefficients for the individual ROIs ranging from 0.999 for the rostrum to 0.987 for the posterior mid-body.

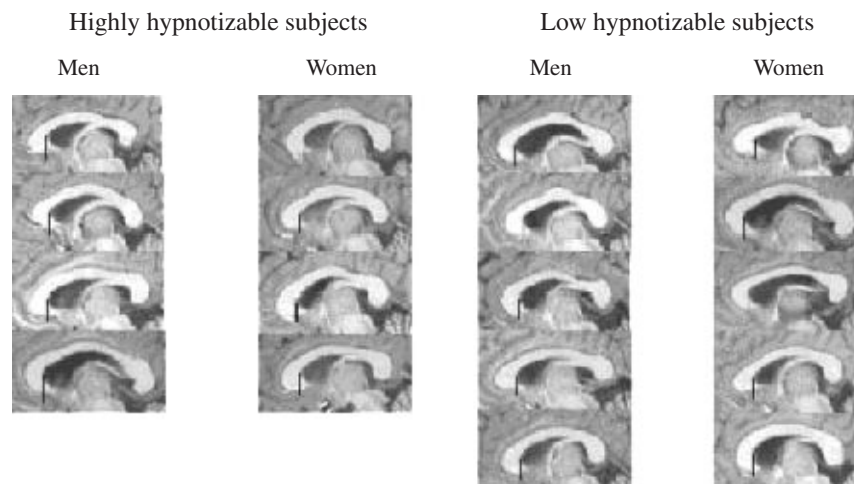
To evaluate interrater reliability, a graduate student trained in the procedure, who was also unaware of the group assignment, measured the ROIs and the total callosal area in one randomly chosen image from each subject. The correlation coefficient for interrater reliability for all measurements of the corpus callosum was 0.950.

### Results

Overall, as expected and seen in Fig. 2, HHs had a significantly larger rostrum than LHs [HHs:  $M = 302$  pixels,  $SD = 64.4$ ;



**Fig. 2** Rostrum volume in the corpus callosum for highly (HH) and low (LH) hypnotizable participants. HHs had significantly larger rostrums than did LHs.



**Fig. 3** Corpus callosum images (400 × 200 pixels), 2 mm into the left hemisphere, for male and female participants in high and low hypnotizability groups. Line depicts rostrum division.

LHs:  $M = 169$  pixels,  $SD = 39.6$ ;  $F(1,14) = 28.533$ ;  $P < 0.0001$ . There were no significant main effects or interactions for sex. There were no significant main effects or interactions in other corpus callosum regions or in overall corpus callosum area.

Using only the rostrum data, a discriminant analysis determined that 100% of the LHs and 87.5% of the HHs were classified correctly into their group membership (Wilk's  $\lambda = 0.311$ ;  $\chi^2(2) = 17.50$ ;  $P < 0.001$ ).

Figure 3 presents one corpus callosum image, 2 mm into the left hemisphere, for each participant.

## Discussion

The primary finding of this study is that HHs, who exhibited more effective attentional and inhibitory capabilities, including demonstrated inhibitory control of pain, had a significantly larger rostrum in the anterior corpus callosum than did LHs. To our knowledge, this is the first MRI study to report a relationship between corpus callosum rostrum size and attentional/inhibitory abilities for healthy individuals. The observed difference in rostrum morphology between HHs and LHs supports a robust literature of behavioural and neurophysiological differences associated with hypnotizability, as reviewed in the Introduction. The data also support the theoretical models (Crawford and Gruzelier, 1992; Crawford, 1994; Hilgard and Hilgard, 1994) that successful control of pain and/or distress with hypnotic analgesia is due, in part, to frontal lobe processes more effectively interacting with and inhibiting downward to other cortical and subcortical areas of the brain (Crawford *et al.*, 1993, 1998a, 1999, 2000; Crawford, 1994; Wik *et al.*, 1999). Furthermore, the study supports findings of an inverse relationship between anterior corpus callosum size and inhibitory frontal lobe deficits, such as is often found in individuals with ADHD (Hynd *et al.*, 1991; Giedd *et al.*, 1994, 2001; Baumgardner *et al.*, 1996; Mataro *et al.*, 1997). Gender differences of the area of the total corpus callosum and some of its subregions, much discussed in the

literature but also generally discounted (Bishop and Wahlsten, 1997), were not observed in the present study.

Our results suggest that the rostrum, in concert with the frontal cortices, may play a crucial role in the deployment of attentional and inhibitory control (Giedd *et al.*, 1994; Banich, 2003), and influence the effectiveness of the frontal cortices in sensory gating (Knight *et al.*, 1999). Interhemispheric interaction may be used as a general strategy to facilitate cognitive flexibility and executive control, as well as computational resources (Passarotti *et al.*, 2002). Summarizing her behavioural studies, Banich (2003) proposes that the corpus callosum helps in selective attention, and that greater interhemispheric interaction can modulate attentional capacity where a person attends to one thing and ignores another (much like hypnotic analgesia).

There is a 'remarkable degree of functional specificity with the corpus callosum' (Funnell *et al.*, 2000; p. 920). On the basis of what is known from primate (Pandya and Seltzer, 1986) and human (Tan *et al.*, 1991) callosal connectivity, the rostrum carries fibres between orbitofrontal, and possibly dorsolateral, cortices. These regions are of crucial importance for different attentional processes (e.g. for a review see Miller and Cohen, 2001). The orbitofrontal cortex controls emotional and motivational behaviours (Posner and DiGirolamo, 1998; Gehring and Knight, 2000; Rule *et al.*, 2002; Stuss and Knight, 2002) and decision making (Manes *et al.*, 2002). Germane to our work, a recent dynamic filtering model proposes that the orbitofrontal PFC 'acts to filter or gate neural activity associated with an arousing event' (Rule *et al.*, 2002; p. 265). The dorsolateral PFC monitors cognition to develop efficient control in the presence of interfering stimuli. Lorenz and colleagues observed that the dorsolateral PFC is activated during painful stimulation, and exerts active control on pain perception by modulating corticocortical and corticocortical pathways (Lorenz *et al.*, 2002, 2003). Using the same individuals as studied in the present research, Crawford *et al.* (2000) noted shifts in fMRI activation in these regions during hypnotically

suggested analgesia. Furthermore, the frontal region showed increased rCBF activation when highly hypnotizable subjects eliminated all perception of sensory and distress to ischaemic pain (Crawford *et al.*, 1993), increased PET activation when fibromyalgia patients used hypnosis to reduce pain (Wik *et al.*, 1999) and increased fMRI activation when participants were successfully distracted during painful stimulation (Bantick *et al.*, 2002).

The functional topographical organization of the corpus callosum, more so the anterior than the posterior regions, is not yet fully understood. The inference of corpus callosum connectivity to the PFC and inhibitory abilities must be tentative, and was based on limited human studies showing corpus callosum projections of the first centimetre of the corpus callosum, the rostrum, to be primarily in the most anterior portion of the PFC (e.g. Tan *et al.*, 1991). Additionally, the anterior commissure has some orbitofrontal axons traversing it (Pandya and Seltzer, 1986). Interestingly, there were no hypnotizability differences noted in the adjoining genu. The axons of the genu, which transverse inferior frontal and anterior/inferior parietal regions (De Lacoste *et al.*, 1985), develop separately from the rostrum (for two differing developmental views, see Kier and Truwit, 1997; Rakic and Yakovlev, 1968). Whether there may also be limited non-corresponding heterotopic connections from the rostrum to other contralateral hemisphere regions is not known (Innocenti and Bressoud, 2003). There is indeed a need for further studies of corpus callosum projection and connectivity using more advanced techniques such as diffusion tensor imaging (for a review see Moseley *et al.*, 2000). Another approach is examining the morphological shape, rather than area, differences of the corpus callosum (Bookstein, 2003). Clearly this is an area requiring fuller research into the inter-relationships between individual differences in attentional and inhibitory abilities, PFC functioning and morphological differences, not only of the corpus callosum, but also the anterior commissure (Pandya and Seltzer, 1986) and the PFC regions.

There are limitations to our study that should be considered. First, our sample size was rather small. However, we included only stringently screened participants and only those of extreme low and high hypnotic susceptibility. 'Virtuoso' HHs in the present study could completely eliminate all perception of pain and distress to experimental noxious pain (cold pressor, electrical stimulation) with suggested hypnotic analgesia. Small sample sizes are a problem if results are negative due to potential power limitations, and thus additional differences might be observed with a larger sample. That we found highly significant differences supports the extent of the rostrum finding in question. The methodology we used was sound (Witelson, 1985; Clarke *et al.*, 1989). The intra- and inter-reliabilities of our blinded measurements were excellent.

## Conclusions

The present investigation is the first to compare the corpus callosum size of stringently selected low and highly hypnotizable individuals, and to demonstrate that HHs have a

significantly larger rostrum than do LHs within a healthy, young adult sample. These results support the neuropsychophysiological model (Crawford and Gruzelier, 1992; Crawford, 1994; Horton and Crawford, 2004) that HHs have more effective frontal attentional systems implementing control, monitoring performance and inhibiting unwanted stimuli from conscious awareness. Morphological studies of correlates of executive processes are quite recent and have centred on clinical populations. This study detected *in vivo* structural brain differences in healthy participants, and thus emphasizes the need for further research examining associations between individual differences in attentional and inhibitory executive control and brain morphology within healthy as well as clinical populations.

## Acknowledgements

We wish to thank T. Hirsch Downs and Susan Daugherty for their assistance, and Xavier Castellanos, Eran Zaidel and anonymous reviewers for their in-depth evaluation of and suggestions on our analyses and text. This work was supported by an ASPIRES grant from the Virginia Polytechnic Institute and State University to H.J.C. and internal support from the University of Virginia Pratt Fund to J.H.D.

## References

- Aboitiz F. Brain connections: interhemispheric fiber systems and anatomical brain asymmetries in humans. *Biol Res* 1992; 25: 51–61.
- Aboitiz F, Ide A, Olivares R. Corpus callosum morphology in relation to cerebral asymmetries in the postmortem human. In: Zaidel E, Iacoboni M, editors. *The parallel brain: the cognitive neuroscience of the corpus callosum*. Cambridge (MA): MIT Press; 2003. p. 33–46.
- Acosta E Jr, Crawford HJ. Iconic memory and hypnotizability: processing speed, skill, or strategy differences? *Int J Clin Exp Hypn* 1985; 33: 236–45.
- Alexander GE, Newman JD, Symmes D. Convergence of prefrontal and acoustic inputs upon neurons in the superior temporal gyrus of the awake squirrel monkey. *Brain Res* 1976; 116: 334–8.
- Annett M. A classification of hand preference by association analysis. *Br J Psychol* 1970; 61: 303–21.
- Banich MT. Interhemispheric interaction: mechanisms of unified processing. In: Kitterle FL, editor. *Hemispheric communication: mechanisms and models*. Hillsdale (NJ): Lawrence Erlbaum; 1995. p. 271–300.
- Banich MT. The missing link: the role of interhemispheric interaction in attentional processing. *Brain Cogn* 1998; 36: 128–57.
- Banich MT. Interacting hemispheres: a means of modulating attention. In: Zaidel E, Iacoboni M, editors. *The parallel brain: the cognitive neuroscience of the corpus callosum*. Cambridge (MA): MIT Press; 2003. p. 267–70.
- Bantick SJ, Wise RG, Ploghaus A, Clare S, Smith SM, Tracey I. Imaging how attention modulates pain in humans using functional MRI. *Brain* 2002; 125: 310–9.
- Baumgardner TL, Singer HS, Denckla MB, Rubin MA, Abrams MT, Colli MJ, et al. Corpus callosum morphology in children with Tourette syndrome and attention deficit hyperactivity disorder. *Neurology* 1996; 47: 477–82.
- Beck AT, Ward CH, Mendelson M, Mock J, Erbaugh J. An inventory for measuring depression. *Arch Gen Psychiatry* 1961; 4: 561–71.
- Bigler ED, editor. *Neuroimaging: 1. Basic science. Human brain function: assessment and rehabilitation*. New York: Plenum Press; 1996.
- Bishop KM, Wahlsten D. Sex differences in the human corpus callosum: myth or reality? *Neurosci Biobehav Rev* 1997; 21: 581–601.

- Bookstein FL. Morphometrics for callosal shape studies. In: Zaidel E, Iacoboni M, editors. *The parallel brain: the cognitive neuroscience of the corpus callosum*. Cambridge (MA): MIT Press; 2003. p. 75–92.
- Boutros NN, Belger A. Midlatency evoked potentials attenuation and augmentation reflect different aspects of sensory gating. *Biol Psychiatry* 1999; 45: 917–22.
- Braff DL, Geyer MA. Sensorimotor gating and schizophrenia. Human and animal model studies. *Arch Gen Psychiatry* 1990; 47: 181–8.
- Braun CMJ, Achim A, Larocque C. The evolution of the concept of interhemispheric relay time. In: Zaidel E, Iacoboni M, editors. *The parallel brain: the cognitive neuroscience of the corpus callosum*. Cambridge (MA): MIT Press; 2003. p. 237–58.
- Chao LL, Knight RT. Human prefrontal lesions increase distractibility to irrelevant sensory inputs. *Neuroreport* 1995; 6: 1605–10.
- Chiarello, C. Does the corpus callosum play a role in the activation and suppression of ambiguous word meanings? In: Kitterle FL, editor. *Hemispheric communication: mechanisms and models*. Hillsdale (NJ): Lawrence Erlbaum; 1995. p. 177–88.
- Clarke S, Kraftsik R, Van der Loos H, Innocenti GM. Forms and measures of adult and developing human corpus callosum: is there sexual dimorphism? *J Comp Neurol* 1989; 280: 213–30.
- Cook ND. *The brain code: mechanisms of information transfer and the role of the corpus callosum*. London: Methuen; 1986.
- Cox RW. MCW AFNI—User manual: analysis of functional neuroimages, Version 2.00. Madison (WI): Medical College of Wisconsin; 1996.
- Crawford HJ. Cognitive and psychophysiological correlates of hypnotic responsiveness and hypnosis. In: Fass ML, Brown D, editors. *Creative mastery in hypnosis and hypnoanalysis: a Festschrift for Erika Fromm*. Hillsdale (NJ): Lawrence Erlbaum; 1990. p. 155–68.
- Crawford HJ. Brain dynamics and hypnosis: attentional and disattentional processes. *Int J Clin Exp Hypn* 1994; 42: 204–32.
- Crawford HJ, Gruzelier JH. A midstream view of the neuropsychophysiology of hypnosis: recent research and future directions. In: Fromm E, Nash MR, editors. *Contemporary hypnosis research*. New York: Guilford Press; 1992. p. 227–66.
- Crawford HJ, Gur RC, Skolnick B, Gur RE, Benson DM. Effects of hypnosis on regional cerebral blood flow during ischemic pain with and without suggested hypnotic analgesia. *Int J Psychophysiol* 1993; 15: 181–95.
- Crawford HJ, Harrison DW, Kapelis L. Visual field asymmetry in facial affect perception: moderating effects of hypnosis, hypnotic susceptibility level, absorption, and sustained attentional abilities. *Int J Neurosci* 1995; 82: 11–23.
- Crawford HJ, Clarke SW, Kitner-Triolo M. Self-generated happy and sad emotions in low and highly hypnotizable persons during waking and hypnosis: laterality and regional EEG activity differences. *Int J Psychophysiol* 1996; 24: 239–66.
- Crawford HJ, Horton JE, Harrington GC, Vendemia JMC, Plantec MB, Jung S, et al. Hypnotic analgesia (disattending pain) impacts neuronal network activation: an fMRI study of noxious somatosensory TENS stimuli. *Neuroimage* 1998a; 7: S436.
- Crawford HJ, Horton JE, Lamas J. Information processing speed is faster for highly hypnotizable than low hypnotizable persons: evidence from behavioral reaction time and event-related potential studies. *Int J Psychophysiol* 1998b; 30: 84.
- Crawford HJ, Knebel T, Kaplan L, Vendemia JMC, Xie M, Jamison S, et al. Hypnotic analgesia: 1. Somatosensory event-related potential changes to noxious stimuli and 2. Transfer learning to reduce chronic low back pain. *Int J Clin Exp Hypn* 1998c; 46: 92–132.
- Crawford HJ, Knebel T, Vendemia JMC, Horton JE. La naturaleza de la analgesia hipnótica: bases y evidencias neurofisiológicas. *Anal Psicol* 1999; 15: 133–46.
- Crawford HJ, Horton JE, Harrington GS, Hirsch-Downs T, Fox K, Downs JH III. fMRI differences in attend and hypnotic analgesia: evidence for differential activation of pain systems. *Neuroimage* 2000; 11: S44.
- De Lacoste MC, Kirkpatrick JB, Ross ED. Topography of the human corpus callosum. *J Neuropathol Exp Neurol* 1985; 44: 578–91.
- De Pascalis V. Event-related potentials during hypnotic hallucination. *Int J Clin Exp Hypn* 1994; 42: 39–55.
- De Pascalis V, Perrone M. EEG asymmetry and heart rate during experience of hypnotic analgesia in high and low hypnotizables. *Int J Psychophysiol* 1996; 21: 163–75.
- Downs JH III, Lancaster JL, Fox PT. Surface based spatial normalization using convex hulls. In: Toga AW, editor. *Brain warping*. San Diego: Academic Press; 1999. p. 263–84.
- Edinger HM, Siegel A, Troiano R. Effect of stimulation of prefrontal cortex and amygdala diencephalic neurons. *Brain Res* 1975; 97: 17–31.
- Funnell MG, Corballis PM, Gazzaniga MS. Insights into the functional specificity of the human corpus callosum. *Brain* 2000; 123: 920–6.
- Gazzaniga MS. Principles of human brain organization derived from split-brain studies. *Neuron* 1995; 14: 217–28.
- Gehring WJ, Knight RT. Prefrontal-cingulate interactions in action monitoring. *Nat Neurosci* 2000; 3: 516–20.
- Giedd JN, Castellanos FX, Casey BJ, Kozuch P, King AC, Hamburger SD, et al. Quantitative morphology of the corpus callosum in attention deficit hyperactivity disorder. *Am J Psychiatry* 1994; 151: 665–9.
- Giedd JN, Blumenthal J, Molloy E, Castellanos FX. Brain imaging of attention deficit/hyperactivity disorder. *Ann N Y Acad Sci* 2001; 931: 33–49.
- Gruzelier J. Hypnosis from a neurobiological perspective: a review of evidence and applications to improve immune function. *Anal Psicol* 1999; 15: 111–32.
- Hesslinger B, Tebartz van Elst L, Thiel T, Haegle K, Hennig J, Elbert D. Fronto-orbital volume reductions in adult patients with attention deficit hyperactivity disorder. *Neurosci Lett* 2002; 328: 319–21.
- Hilgard ER, Hilgard JR. *Hypnosis in the relief of pain*. Rev. ed. New York: Brunner/Mazel; 1994.
- Horton JE, Crawford HJ. Neurophysiological and genetic determinants of high hypnotisability. In: Heap M, Brown RJ, Oakley DA, editors. *High hypnotisability: theoretical, experimental and clinical issues*. London: Brunner/Routledge. In press 2004.
- Hynd GW, Semrud-Clikeman M, Lorys AR, Novey ES, Eliopoulos D, Lyytinen H. Corpus callosum morphology in attention deficit-hyperactivity disorder: morphometric analysis of MRI. *J Learn Disabil* 1991; 24: 141–6.
- Innocenti GM, Bressoud R. Callosal axons and their development. In: Zaidel E, Iacoboni M, editors. *The parallel brain: the cognitive neuroscience of the corpus callosum*. Cambridge (MA): MIT Press; 2003. p. 11–26.
- Jancke L, Steinmetz H. Interhemispheric transfer time and corpus callosum size. *Neuroreport* 1994; 5: 2385–8.
- Judd LL, McAdams L, Budnick B, Braff DL. Sensory gating deficits in schizophrenia: new results. *Am J Psychiatry* 1992; 149: 488–93.
- Karol EA, Pandya DN. The distribution of the corpus callosum in the Rhesus monkey. *Brain* 1971; 94: 472–86.
- Kier EL, Truwit CL. The lamina rostralis: modification of concepts concerning the anatomy, embryology, and MR appearance of the rostrum of the corpus callosum. *AJNR Am J Neuroradiol* 1997; 18: 715–22.
- Knight RT, Staines WR, Swick D, Chao LL. Prefrontal cortex regulates inhibition and excitation in distributed neural networks. *Acta Psychol (Amst)* 1999; 101: 159–78.
- Kropotov JD, Crawford HJ, Polyakov YI. Somatosensory event-related potential changes to painful stimuli during hypnotic analgesia: anterior cingulate cortex and anterior temporal cortex intracranial recordings. *Int J Psychophysiol* 1997; 27: 1–8.
- Lorenz J, Cross D, Minoshima S, Morrow T, Paulson P, Casey K. A unique representation of heat allodynia in the human brain. *Neuron* 2002; 35: 383–93.
- Lorenz J, Minoshima S, Casey KL. Keeping pain out of mind: the role of the dorsolateral prefrontal cortex in pain modulation. *Brain* 2003; 126: 1079–91.
- MacLeod-Morgan C, Lack L. Hemispheric specificity: a physiological concomitant of hypnotizability. *Psychophysiology* 1982; 19: 687–90.
- Manes F, Sahakian B, Clark L, Rogers R, Antoun N, Aitken M, et al. Decision-making processes following damage to the prefrontal cortex. *Brain* 2002; 125: 624–39.
- Mataro M, Garcia-Sanchez C, Junque C, Estevez-Gonzalez A, Pujol J. Magnetic resonance imaging measurement of the caudate nucleus in adolescents

- with attention-deficit hyperactivity disorder and its relationship with neuropsychological and behavioral measures. *Arch Neurol* 1997; 54: 963–8.
- Mészáros I, Crawford HJ, Szabó C, Nagy-Kovács A, Révész MA. Hypnotic susceptibility and cerebral hemisphere preponderance: verbal-imaginal discrimination task. In: Gheorghiu V, Netter P, Eysenck H, Rosenthal R, editors. *Suggestion and suggestibility: theory and research*. Berlin: Springer-Verlag; 1989. p. 191–204.
- Miller ME, Bowers KS. Hypnotic analgesia: dissociated experience or dissociated control? *J Abnorm Psychol* 1993; 102: 29–38.
- Miller EK, Cohen JD. An integrative theory of prefrontal cortex function. *Annu Rev Neurosci* 2001; 24: 167–202.
- Moseley M, Bammer R, Illes J. Diffusion-tensor imaging of cognitive performance. *Brain Cogn* 2000; 50: 396–413.
- Nordby H, Hugdahl K, Jasiukaitis P, Spiegel D. Effects of hypnotizability on performance of a Stroop task and event-related potentials. *Percept Mot Skills* 1999; 88: 819–30.
- Pandya DN, Seltzer F. The topography of commissural fibers. In: Lepore F, Pito M, Jasper HH, editors. *Two hemispheres—one brain: functions of the corpus callosum*. New York: Alan R. Liss; 1986. p. 47–73.
- Passarotti AM, Banich MT, Sood RK, Wang JM. A generalized role of inter-hemispheric interaction under attentionally demanding conditions: evidence from the auditory and tactile modality. *Neuropsychologia* 2002; 40: 1082–96.
- Posner MI, DiGirolamo GJ. Executive attention: Conflict, target detection, and cognitive control. In: Parasuraman R, editor. *The attentive brain*. Cambridge (MA): MIT Press; 1998. p. 401–23.
- Rainville P, Duncan GH, Price DD, Carrier B, Bushnell MC. Pain affect encoded in human anterior cingulate but not somatosensory cortex. *Science* 1997; 277: 968–71.
- Rainville P, Hofbauer RK, Paus T, Duncan GH, Bushnell MC, Price DD. Cerebral mechanisms of hypnotic induction and suggestion. *J Cogn Neurosci* 1999; 11: 110–25.
- Rainville P, Hofbauer RK, Bushnell MC, Duncan GH, Price DD. Hypnosis modulates activity in brain structures involved in the regulation of consciousness. *J Cogn Neurosci* 2002; 14: 887–901.
- Rakic P, Yakovlev PI. Development of the corpus callosum and cavum septi in man. *J Comp Neurol* 1968; 132: 45–72.
- Rueckert L, Levy J. Further evidence that the callosum is involved in sustaining attention. *Neuropsychologia* 1996; 34: 927–35.
- Rule RR, Shimamura AP, Knight RT. Orbitofrontal cortex and dynamic filtering of emotional stimuli. *Cogn Affect Behav Neurosci* 2002; 2: 264–70.
- Sabourin ME, Cutcomb SD, Crawford HJ, Pribram K. EEG correlates of hypnotic susceptibility and hypnotic trance: spectral analysis and coherence. *Int J Psychophysiol* 1990; 10: 125–42.
- Shor RE, Orne EC. *Harvard Group Scale of Hypnotic Susceptibility: Form A*. Palo Alto (CA): Consulting Psychologists Press; 1962.
- Skinner JE, Yingling CD. Central gating mechanisms that regulate event-related potentials and behavior: a neural model for attention. In: Desmedt JE, editor. *Attention, voluntary contraction and event-related cerebral potentials*. Progress in clinical neurophysiology, Vol. 1. Basel: Karger; 1977. p. 28–68.
- Staines WR, Graham SJ, Black SE, McIlroy WE. Task-relevant modulation of contralateral and ipsilateral primary somatosensory cortex and the role of a prefrontal-cortical sensory gating system. *Neuroimage* 2002; 15: 190–9.
- Stuss DT, Knight RT. Prefrontal cortex: the present and the future. In: Stuss DT, Knight RT, editors. *Principles of frontal lobe function*. Oxford: Oxford University Press; 2002. p. 573–97.
- Talairach J, Tournoux P. *Co-planar stereotaxic atlas of the human brain: 3-dimensional proportional system: an approach to cerebral imaging*. Stuttgart: Thieme; 1988.
- Tan YL, Chen BH, Yang JD, Zhang J, Wang YC, Chai SH, et al. Localization of functional projections from corpus callosum to cerebral cortex. *Chin Med J (Engl)* 1991; 104: 851–7.
- Van Essen DC, Newsome WT, Bixby JL. The pattern of interhemispheric connections and its relationship to extrastriate visual areas in the macaque monkey. *J Neurosci* 1982; 2: 265–83.
- Weitzenhoffer AM, Hilgard ER. *Stanford Hypnotic Susceptibility Scale, Form C*. Palo Alto (CA): Consulting Psychologists Press; 1962.
- Wik G, Fischer H, Bragee B, Finer B, Fredrikson M. Functional anatomy of hypnotic analgesia: a PET study of patients with fibromyalgia. *Eur J Pain* 1999; 3: 7–12.
- Witelson SF. The brain connection: the corpus callosum is larger in left-handers. *Science* 1985; 229: 665–8.
- Yamaguchi S, Knight RT. Gating of somatosensory input by human prefrontal cortex. *Brain Res* 1990; 521: 281–8.
- Yingling CD, Skinner JE. Gating of thalamic input to cerebral cortex by nucleus reticularis thalami. In: Desmedt JE, editor. *Attention, voluntary contraction and event-related cerebral potentials*. Progress in clinical neurophysiology, Vol. 1. Basel: Karger; 1977. p. 70–96.
- Zaidel E, Iacoboni M, editors. *The parallel brain: the cognitive neuroscience of the corpus callosum*. Cambridge (MA): MIT Press; 2003.