

A phase I trial of adeno-associated virus serotype 1- γ -sarcoglycan gene therapy for limb girdle muscular dystrophy type 2C

Serge Herson,¹ Faycal Hentati,² Aude Rigolet,¹ Anthony Behin,³ Norma B. Romero,³ France Leturcq,⁴ Pascal Laforêt,³ Thierry Maissonobe,³ Rim Amouri,² Hamed Haddad,⁵ Muriel Audit,⁶ Marie Montus,⁵ Carole Masurier,⁵ Bernard Gjata,⁵ Christophe Georger,⁵ Mustapha Cheraï,⁷ Pierre Carlier,³ Jean-Yves Hogrel,³ Ariane Herson,³ Yves Allenbach,¹ François M. Lemoine,⁷ David Klatzmann,⁷ H. Lee Sweeney,⁸ Richard C. Mulligan,⁹ Bruno Eymard,³ Didier Caizergues,⁵ Thomas Voit³ and Olivier Benveniste¹

1 Université Pierre et Marie Curie, Assistance Publique-Hôpitaux de Paris, Hôpital Pitié-Salpêtrière, Médecine Interne 1, Paris 75013, France

2 Department of Molecular Neurobiology and Neuropathology, National Institute of Neurology, La Rabta, Tunis 1007, Tunisia

3 Université Pierre et Marie Curie, Assistance Publique-Hôpitaux de Paris, Hôpital Pitié-Salpêtrière, Institut de Myologie, Paris 75013, France

4 Assistance Publique-Hôpitaux de Paris, Hôpital Cochin, Laboratoire Biochimie Génétique, Paris 75014, France

5 Genethon, Evry 91000, France

6 Genosafe, Evry, 91000, France

7 Université Pierre et Marie Curie, Assistance Publique-Hôpitaux de Paris, Hôpital Pitié-Salpêtrière, CNRS UMR 7211, Paris 75013, France

8 Department of Physiology, School of Medicine, University of Pennsylvania, Philadelphia, PA 19104, USA

9 Harvard Gene Therapy Initiative, Department of Genetics, Harvard Medical School, Boston, MA 02115, USA

Correspondence to: Olivier Benveniste,
Service de Médecine Interne 1,
Groupe Hospitalier Pitié-Salpêtrière,
47-83, boulevard de l'Hôpital,
75651 Paris Cedex 13, France
E-mail: olivier.benveniste@psl.aphp.fr

γ -Sarcoglycanopathy or limb girdle muscular dystrophy type 2C is an untreatable disease caused by autosomal recessively inherited mutations of the γ -sarcoglycan gene. Nine non-ambulatory patients (two males, seven females, mean age 27 years; range 16–38 years) with del525T homozygous mutation of the γ -sarcoglycan gene and no γ -sarcoglycan immunostaining on muscle biopsy were divided into three equal groups to receive three escalating doses of an adeno-associated virus serotype 1 vector expressing the human γ -sarcoglycan gene under the control of the desmin promoter, by local injection into the extensor carpi radialis muscle. The first group received a single injection of 3×10^9 viral genomes in 100 μ l, the second group received a single injection of 1.5×10^{10} viral genomes in 100 μ l, and the third group received three simultaneous 100- μ l injections at the same site, delivering a total dose of 4.5×10^{10} viral genomes. No serious adverse effects occurred during 6 months of follow-up. All nine patients became adeno-associated virus serotype 1 seropositive and one developed a cytotoxic response to the adeno-associated virus serotype 1 capsid. Thirty days later, immunohistochemical analysis of injected-muscle biopsy specimens showed γ -sarcoglycan expression in all three patients who received the highest dose (4.7–10.5% positively stained fibres), while real-time polymerase chain reaction detected γ -sarcoglycan messenger RNA. In one patient, γ -sarcoglycan protein was

detected by western blot. For two other patients who received the low and intermediate doses, discrete levels of γ -sarcoglycan expression (<1% positively stained fibres) were also detectable. Expression of γ -sarcoglycan protein can be induced in patients with limb girdle muscular dystrophy type 2C by adeno-associated virus serotype 1 gene transfer, with no serious adverse effects.

Keywords: adeno-associated virus; gene transfer; muscular dystrophy
Abbreviations: AAV = adeno-associated virus; γ -SGC = γ -sarcoglycan

Introduction

γ -Sarcoglycanopathies are rare inherited muscular dystrophies belonging to the group of autosomal recessive limb girdle muscular dystrophies (limb girdle muscular dystrophy type 2C) (Bushby and Beckmann, 1995). Sarcoglycans (α -, β -, γ - and δ -) are trans-membrane proteins that form a complex that associates with dystrophin in the muscle fibre membrane (Ozawa *et al.*, 1998). Clinical expression of limb girdle muscular dystrophy type 2C is highly variable: the disease is rapidly progressive in 20–49% of cases with onset in the first decade of life, intermediate in 27–55% and milder in 13–25% (Ben Hamida *et al.*, 1996; Merlini *et al.*, 2000; Kefi *et al.*, 2003). Dilated cardiomyopathy is relatively frequent, particularly in advanced stages (Calvo *et al.*, 2000).

There is currently no specific treatment for limb girdle muscular dystrophy type 2C, but gene therapy might be an option in the future. In a preclinical mouse model based on γ -sarcoglycan (γ -SGC) gene disruption (Hack *et al.*, 1998), animals injected with an adeno-associated virus (AAV) vector expressed γ -SGC in the sarcolemma of muscle fibres and showed an overall improvement in their dystrophic histological pattern (Cordier *et al.*, 2000). These findings, together with reassuring complete safety studies in mice, led us to launch an open-label, dose-escalation, three-cohort (phase I) study of intramuscular delivery of replication-defective AAV (AAV1.des.h γ SGC) expressing γ -SGC. The goal was to examine the safety of AAV1 vector administration and exogenous γ -SGC expression.

Patients and methods

Patients

Nine patients (seven females and two males, average age 27 years, range 16–38 years; Table 1) were selected on the basis of the following criteria: (i) molecular genetic studies showing homozygous del525T mutation of the γ -SGC gene on chromosome 13; (ii) pre-inclusion muscle biopsy on dominant extensor carpi radialis (on Day –30) showing no γ -SGC immunohistochemical staining; (iii) wheelchair dependent but with adequate extensor carpi radialis muscle bulk and strength (MRC \geq 3+) for muscle biopsy and reliable strength assessment; and (iv) no severe cardiac dysfunction (ejection fraction > 30%) or respiratory dysfunction (forced vital capacity > 1000 ml and/or > 30% of normal). Thirty days after vector administration (Day 30), muscle biopsy was performed at the injection site. The patients were tested at Days –30, 0, 15, 30, 60, 120 and 180 for maximal wrist extension strength by means of dynamometry, using standardized operating procedures (Romero *et al.*, 2004). MRI of the forearm was also performed at Days –30 and 15 with a Siemens Trio Tim device operating at 3T. The patients were offered regular interviews with a psychologist during the study, to provide support and to assess the psychological impact of trial participation.

All clinical, MRI and biological findings, including immunohistochemical findings on muscle biopsy specimens and immunological data, were analysed by a steering committee, including independent experts, who authorized the enrolment of the next patient. All nine enrolled patients completed the protocol.

The protocol was submitted to independent committees, as required by French legislation on clinical trials of gene therapy products

Table 1 Characteristics of the patients and AAV1.des.h γ -SGC diffusion and expression in injected muscles

Patient no., sex, age (years), weight (kg)	Age at loss of walking ability (years)	Dose of AAV1 injected (viral genomes)	AAV1 (copies/ μ g DNA)	γ -SGC mRNA (copies/ μ g RNA)	γ -SGC immunohistochemistry (percentage of fully labelled muscle fibres)	γ -SGC western blot
01, F, 38, 65	30	3×10^9	2.8×10^3	UD	UD	UD
02, F, 18, 60	12	3×10^9	0.5×10^3	UD	UD	UD
03, F, 32, 63	16	3×10^9	0.2×10^3	UD	0.1	UD
04, F, 16, 68	15	1.5×10^{10}	UD	UD	UD	UD
05, M, 24, 108	15	1.5×10^{10}	0.4×10^3	UD	UD	UD
06, M, 29, 50	16	1.5×10^{10}	8.3×10^3	1.4×10^4	0.4	UD
07, F, 38, 57	21	4.5×10^{10}	4.9×10^5	9.3×10^4	8	UD
08, F, 31, 36	20	4.5×10^{10}	3.1×10^5	3.5×10^4	4.7	UD
09, F, 19, 49	15	4.5×10^{10}	1.7×10^6	1.5×10^5	10.5	Positive

AAV1.des.h γ -SGC was injected in the non-dominant extensor carpi radialis muscle at Day 0. Muscle biopsies were performed at Day 30 in the latter for AAV1 and γ -SGC messenger RNA detection (by polymerase chain reaction and real-time polymerase chain reaction, respectively), γ -SGC immunohistochemistry and γ -SGC western blot. F = female; M = male; UD = undetectable.

(Molecular Engineering Committee and Genetic Engineering Committee) and was finally approved by the French Health Products Safety Agency (AFSSAPS) as a phase I clinical study without expected benefit. The committees recommended that the gene therapy product was injected in the non-dominant extensor carpi radialis muscle, excluding a randomized blinded placebo controlled trial. The protocol was also approved by the Pitié-Salpêtrière Hospital ethics committee, receiving the Eudract no. 2006-005132-24, ISRCTN no. 22225367 and clinicalTrials.gov no. NCT01344798.

Adeno-associated virus-1 vector preparation

The recombinant pseudotyped AAV1.des.h γ -SGC vector was produced in HEK293 cells by using the three-plasmid transfection protocol, as described elsewhere (Boutin *et al.*, 2010), with the following three GMP-manufactured, CsCl gradient-purified constructs, all containing an ampicillin resistance gene: (i) a pAAV1 plasmid containing the human γ -SGC gene sequence under the control of the desmin promoter, followed by a small segment of exon II, IVSII, exon III and the polyadenylation signal of the human β -globin gene sequence; (ii) a pLT-RCO2 plasmid containing the full Cap coding region and some of the three sequences of the Rep region amplified from wild-type AAV1 viral stocks from the American Type Culture Collection (ATCC), and fused to the appropriate positions of the AAV2 Rep sequences in the parental AAV2 helper construct; and (iii) a pHGTI-Adeno1 plasmid generated by cloning the E2A, E4orf6 and VA RNA regions of the adenovirus genome into the pLitmus vector (New England Biolabs). Plasmid and virus production were performed by the Harvard Gene Therapy Initiative (HGTI) laboratory in CF-10 flasks. The production process included freeze/thaw cell lysis followed by benzonase and detergent treatment, and a two-step purification process based on an iodixanol gradient and column chromatography. The purified bulk eluate was formulated in Dulbecco's phosphate-buffered saline buffer with Calcium and Magnesium and sterile-filtered before freeze storage. Viral genomes were quantified by real-time polymerase chain reaction and vector titres were expressed as viral genomes per millilitre.

Vector administration

All nine patients received AAV1.des.h γ -SGC by injection into the extensor carpi radialis muscle of the non-dominant forearm during open surgery (skin incision 12–15 mm long) under local anaesthesia. AAV1.des.h γ -SGC was injected into the muscle through the aponeurosis (which was not incised), at a depth of 2–4 mm, with an insulin syringe and a 27-gauge needle, between two sutures (as marks) 1 cm apart, which were removed during the Day 30 muscle biopsy procedure. Subjects in Group 1 received a single injection of 3×10^9 viral genomes in 100 μ l. Subjects in Group 2 received a single injection of 1.5×10^{10} viral genomes in 100 μ l. Subjects in Group 3 received three simultaneous injections of 1.5×10^{10} viral genomes, each in 100 μ l (total 4.5×10^{10} viral genomes, 300 μ l), forming a triangle of 2 mm at the incision site.

Muscle biopsy analysis

To examine the local effects of AAV1.des.h γ -SGC administration, a muscle biopsy specimen was collected from the injection site 30 days later (Day 30). The fragment was 10–15 mm long and 3–4 mm wide and was immediately frozen. The entire muscle fragment

was serially sectioned on a cryostat and the sections were distributed, using a pre-established procedure, between histological examination and gene transfer evaluation (Romero *et al.*, 2004). Briefly, a series of 10 sections 20- μ m thick was prepared for western blot (Romero *et al.*, 2004), followed by eight sections 10- μ m thick for haematoxylin–eosin staining, five series of seven sections 8- μ m thick for sarco-glycan and dystrophin immunohistochemistry (Romero *et al.*, 2004) and markers of inflammation (CD4, CD8, CD20cy, MHC-class I, MHC-class II), 10 sections 20- μ m thick for real-time polymerase chain reaction detection of AAV1 DNA and 10 sections 20- μ m thick for real-time polymerase chain reaction detection of exogenous γ -SGC messenger RNA. This series was repeated three times. The primers used for the amplification of the vector DNA are located in the inverted terminal repeat region. The primers used for the amplification of messenger RNA specific to the transgene are located at the end of the transgene sequence and in the polyadenylation site; these primers allow the amplification of messenger RNA specific to the γ -SGC transgene without amplifying RNA specific to the endogenous γ -SGC gene.

Histopathological studies with haematoxylin–eosin and immunohistochemical staining were performed twice. The first examination consisted of a safety assessment before inclusion of the following patient. Then, at the end of the study, the anonymized and randomly distributed slides (from the injected muscle at Day 30 and from the contralateral non-injected muscle at Day –30) were examined blindly by a muscle pathologist independent of the steering committee and study staff. Finally, the percentage of γ -SGC stained fibres and the MHC-class I expression were evaluated automatically with EllixTM and HistolabTM applications (Microvision). The Day 30 biopsy findings were then compared with those obtained in the contralateral extensor carpi radialis muscle on Day –30. Furthermore, for MHC-class I quantification, we also used the biopsy specimens of three healthy subjects as negative controls and of three patients with definite polymyositis and ubiquitous MHC-class I expression as positive controls.

Immune responses to adeno-associated virus-1 and γ -sarcoglycan

The humoral response to AAV1 was measured by enzyme-linked immunosorbent assay on serial dilutions of heat-inactivated serum, as previously described (Boutin *et al.*, 2010). The humoral response to γ -SGC was measured by western blot on C2C12 cells overexpressing human γ -SGC. Neutralizing assay was performed as previously described (Boutin *et al.*, 2010). The neutralizing factor titre was recorded as the highest serum dilution that inhibited AAV transduction by $\geq 50\%$ on HeLa cells.

Cellular immune responses were evaluated with ELISPOT assays (Romero *et al.*, 2004). Briefly, frozen peripheral blood mononuclear cells were plated in interferon- γ -precoated 96-well ELISPOT plates (Mabtech) and incubated in the presence of lentiviral vectors encoding the whole γ -SGC protein or the AAV1 VP1, VP2 and VP3 capsid proteins. Results were recorded as spot-forming units/ 10^6 cells. Samples were considered positive for γ -SGG or VP1 if the ratio between the number of spots for a specific transgene and the corresponding control with lentiviral empty was > 1.5 times (cut-off based on mean ratio of 32 negative donors + 3 SD). Phorbol myristate acetate/ionomycin produced $> 10\,000$ spots per 10^6 cells, anti-CD3 > 3900 spots per 10^6 cells, and CEF [an MHC-class I-restricted pool of 23 peptides that represent T cell epitopes of common human viruses, such as cytomegalovirus, Epstein–Barr virus, influenza virus (Mabtech)] > 100 spots per 10^6 cells.

Results

Tolerability of AAV1.des.h γ -SGC injection

The injections were well tolerated, with no physical or psychological adverse effects, except for an episode of fever that occurred on Day 3 in Patient 5 and resolved spontaneously within 48 h. No local inflammation or swelling was observed.

Muscle strength was stable during the 6-month follow-up period, as assessed by dynamometry, in both the injected and contralateral forearms (Fig. 1). Fat-saturated T₂-weighted MRI showed no hyperintensities in the extensor carpi radialis or other forearm muscles at Day –30 and Day 15. No evidence of myolysis or systemic inflammation was observed during follow-up; in particular, levels of creatine kinase, C-reactive protein, interleukin-6, interleukin-8, interferon- γ , IgA, IgG, IgM, IgE and anti-nuclear/anti-DNA factors remained stable or undetectable. Biopsy specimens showed no inflammatory infiltrates on

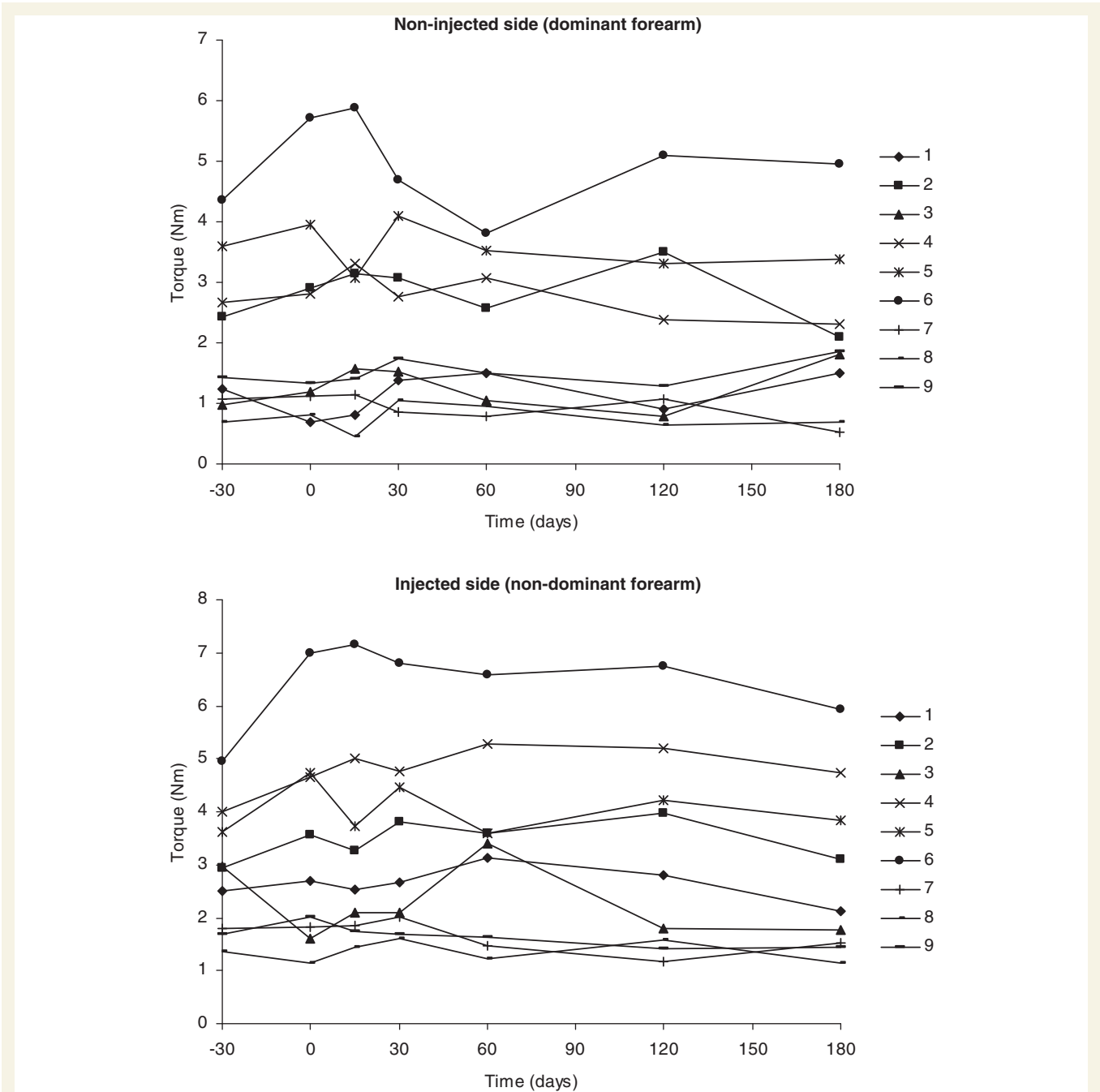


Figure 1 Changes in wrist extension strength in the dominant and non-dominant forearms over time in the nine patients. Muscle biopsies were performed at Day –30 in the dominant extensor carpi radialis muscle and Day 30 in the non-dominant extensor carpi radialis muscle. AAV1.des.h γ -SGC was injected in the latter at Day 0. No significant strength loss occurred in either forearm.

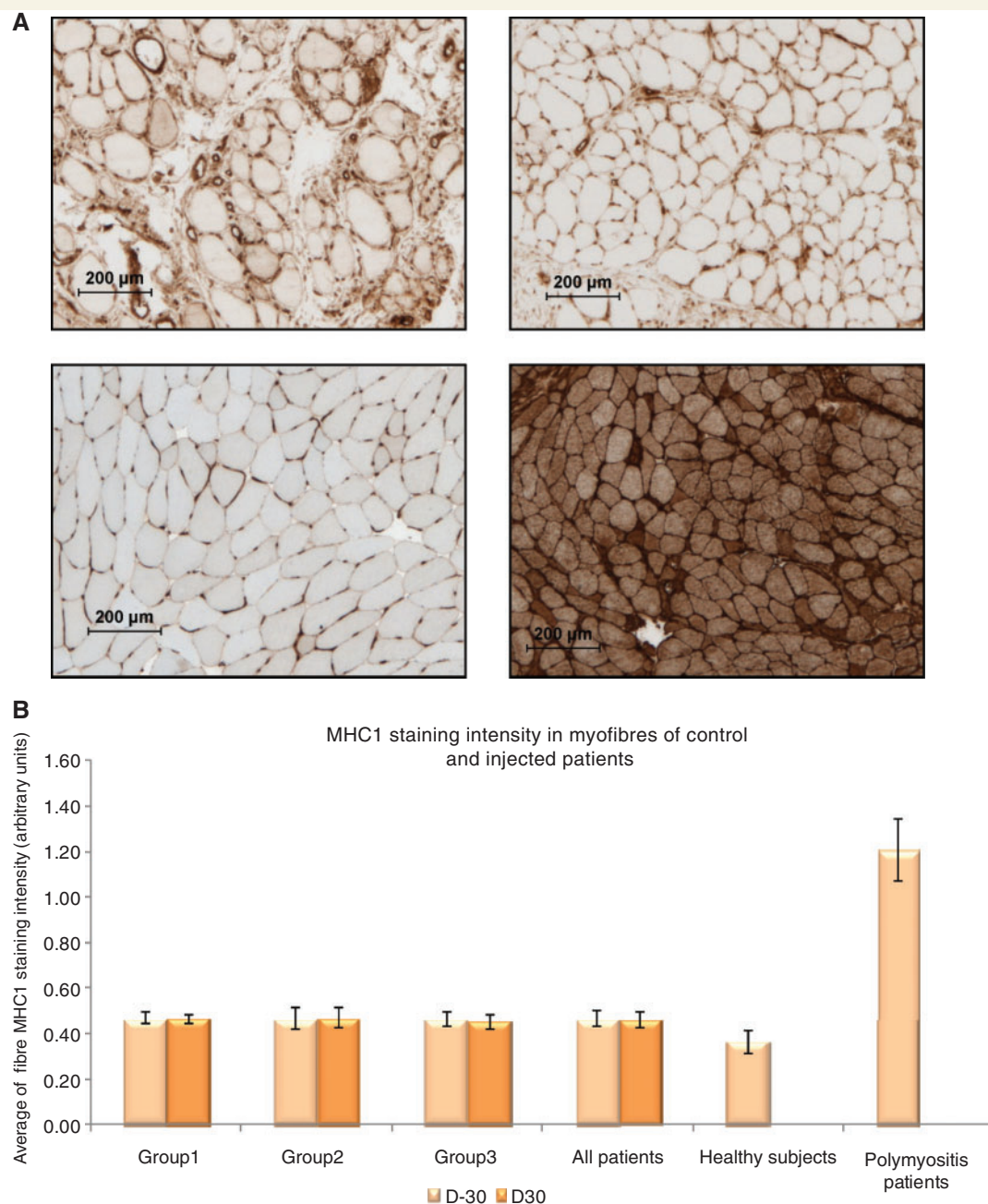


Figure 2 (A) Immunohistochemical detection of MHC-class I in the muscle biopsy specimens from Patient 8 at Day –30 and Day 30, a normal subject and a patient with polymyositis. (B) Quantification of MHC-class I staining assessed by densitometry from the three patients of each doses at Day –30 (D –30) and Day 30 (D 30). The intensities of MHC-class I staining remain stable in AAV injected or not extensor carpi radialis muscles. For comparison, average intensities of all nine patients at Days –30 and 30 were compared to those obtained from three normal subjects and three patients with polymyositis.

haematoxylin–eosin staining and no immunohistochemical evidence of local inflammation (data not shown). MHC-class I expression on muscle fibres was stable (Fig. 2). AAV1.des.h γ -SGC was detected by polymerase chain reaction in peripheral blood mononuclear cells collected from one patient (Patient 8), 12 and 24 h after administration (66 copies/ 4.5×10^4 cells and 49 copies/ 3.6×10^4 cells, respectively), before becoming undetectable at 48 h; and also in urine collected from another

patient 24 h after administration (Patient 3, 4.4×10^3 copies/ml), before becoming undetectable at 48 h.

Transgene expression

Thirty days after AAV1.des.h γ -SGC injection, AAV1 was detected by polymerase chain reaction in the injection-site muscle biopsy samples from all but one of the patients (Patient 4, Table 1).

Patient 3 (Group 1, low dose) and Patient 6 (Group 2, intermediate dose) had discrete wild-type γ -SGC protein staining on immunohistochemistry (a few fibres partially positive, up to 0.4% of fibres fully labelled, Table 1). All three patients who received the highest dose of AAV1.des.h γ -SGC (4.5×10^{10} viral genomes) had detectable γ -SGC RNA and immunohistochemical staining (4.7–10.5% of fibres fully positive, Table 1, Fig. 3A). Wild-type γ -SGC protein was also detected by western blot (Table 1 and Fig. 3B) in Patient 9. γ -SGC expression was accompanied by the detection of SCG complexes (Fig. 3C). No γ -SGC immunolabelling was detected in any of the Day –30 biopsy specimens taken from the contralateral forearm (Fig. 3A).

Immune responses to AAV1.des.h γ -SGC

Patients 2, 5 and 6 were found to have pre-existing anti-AAV1 neutralizing antibodies (Table 2). Patient 7 had seroconverted naturally by Day 0. The remaining five patients were AAV1-seronegative prior to AAV1.des.h γ -SGC administration. All five seronegative patients became AAV1-seropositive at various times after AAV1.des.h γ -SGC injection, but Patients 1, 3 and 4 did not develop neutralizing antibodies (Table 2). Anti-AAV1 antibody titres increased after AAV1.des.h γ -SGC injection in all the pre-immunized patients (Table 2). No anti- γ -SGC antibodies were detected in any of the patients (data not shown).

Patients 2 and 7 were found to be VP1-reactive by ELISPOT before AAV1.des.h γ -SGC injection, but both tested negative on Day 30 (Fig. 4). Patient 8 had a positive cellular immune response to VP1 at all three time points (Days 30, 120 and 180) after AAV1.des.h γ -SGC injection, while Patient 6 was only positive on Day 180 (Fig. 4). No anti- γ -SGC cellular responses were detected by ELISPOT in any of the patients (data not shown).

Discussion

In this phase I trial, intramuscular injection of AAV1.des.h γ -SGC at the highest dose consistently induced exogenous γ -SGC expression, with no serious adverse effects. The low and intermediate doses induced little or no transgene expression, suggesting a dose-related effect. These findings were confirmed by (i) quantification assessed by densitometry; and (ii) real-time and blinded retrospective comparisons of immunohistochemically stained biopsy specimens from the injected extensor carpi radialis muscle and the contralateral uninjected extensor carpi radialis muscle, obtained 1 month after and 1 month before AAV1.des.h γ -SGC administration, respectively.

Gene therapy holds promise for patients with a variety of inherited disorders, and proof of principle has been obtained in animal models. AAV is currently the most promising viral vector (for a review see Heilbronn and Weger, 2010). Some phase I/II human gene therapy trials with AAV vectors and efficient gene transfer have been completed, notably in Leber's congenital amaurosis (with some clinical benefit) (Bainbridge *et al.*, 2008; Cideciyan *et al.*, 2008; Maguire *et al.*, 2008, 2009), haemophilia B (Manno *et al.*, 2003, 2006) and limb girdle muscular dystrophy type 2D (α -SGC deficiency) (Mendell *et al.*, 2009, 2010). In the

latter study, the efficacy demonstrated using the low dose precluded the need to expose patients to higher viral doses (Mendell *et al.*, 2009). The six treated patients received a local intramuscular injection of 3.25×10^{11} viral genomes (about seven times the highest dose used here) of an AAV1 vector carrying the α -SGC gene under the control of a truncated muscle-specific muscle creatine kinase promoter. Immunohistochemical α -SGC staining was more intense than in our study, with 57–62% of fibres positive (Mendell *et al.*, 2009) and persisted for 6 months (Mendell *et al.*, 2010). This difference may be due to the use of a higher injected dose, but it should also be noted that at baseline, patients had detectable α -SGC staining by immunohistochemistry or western blot (Mendell *et al.*, 2009, 2010). The use of different promoters might also have contributed to the observed difference in transgene expression.

No serious adverse effects have so far been noted in the 200-plus patients who have received different AAV subtypes, at different doses, via different routes and in different indications (Manno *et al.*, 2003, 2006; Kaplitt *et al.*, 2007; Moss *et al.*, 2007; Bainbridge *et al.*, 2008; Cideciyan *et al.*, 2008; Maguire *et al.*, 2008, 2009; Stroes *et al.*, 2008; Brantly *et al.*, 2009; Jaski *et al.*, 2009; Mendell *et al.*, 2009). Nevertheless, transgene expression can be compromised by immune responses to AAV (Manno *et al.*, 2006; Mendell *et al.*, 2010) and/or to the exogenous wild-type protein (Mendell *et al.*, 2010). We observed no signs of non-specific inflammatory reactions such as local pain, swelling, erythema or inflammatory marker elevation. Pre-existing anti-AAV neutralizing antibodies can limit transduction efficiency, both in humans (Manno *et al.*, 2006; Mendell *et al.*, 2010) and in animal models (Riviere *et al.*, 2006). We have previously found that the prevalence of anti-AAV1 neutralizing antibodies is ~50% in the general French population (Boutin *et al.*, 2010). Thus, the lack of detectable γ -SGC in Patients 2 and 5, who had neutralizing antibodies to AAV1 before AAV1.des.h γ -SGC injection, might have been due to this pre-existing immunity, as we have observed in mice after repeated intramuscular administration (Riviere *et al.*, 2006). In order to avoid this potential confounding factor, and with ethics committee approval, we decided to include only AAV-seronegative patients in the group receiving the highest dose of AAV1- γ -SGC. All five previously seronegative patients developed anti-AAV1 antibodies, between 15 and 180 days after AAV1- γ -SGC injection. Neutralizing antibodies were detected in only two patients (Patients 8 and 9). Pre-immunized patients exhibited a recall response (stronger and more rapid), suggesting a trigger effect. Regarding the cellular immune response mediated by cytotoxic CD8⁺ T cells, two patients with haemophilia B treated by hepatic artery injection of a gene therapy product (Manno *et al.*, 2006) had a transient, self-limited elevation of liver enzymes, a concomitant decline in factor IX to pretreatment levels, and AAV capsid-specific CD8⁺ T cell expansion, suggesting immune destruction of transduced hepatocytes (Manno *et al.*, 2006). Similarly, patients with lipoprotein lipase deficiency receiving intramuscular injections of AAV1-lipoprotein lipase^{S447X} (10^{11} or 3×10^{11} viral genomes/kg) exhibited a loss of efficacy at later time points (18–31 months), possibly due to a T cell response to AAV1 capsid proteins (Stroes *et al.*, 2008). Thus, pre-existing memory T cells specific for AAV

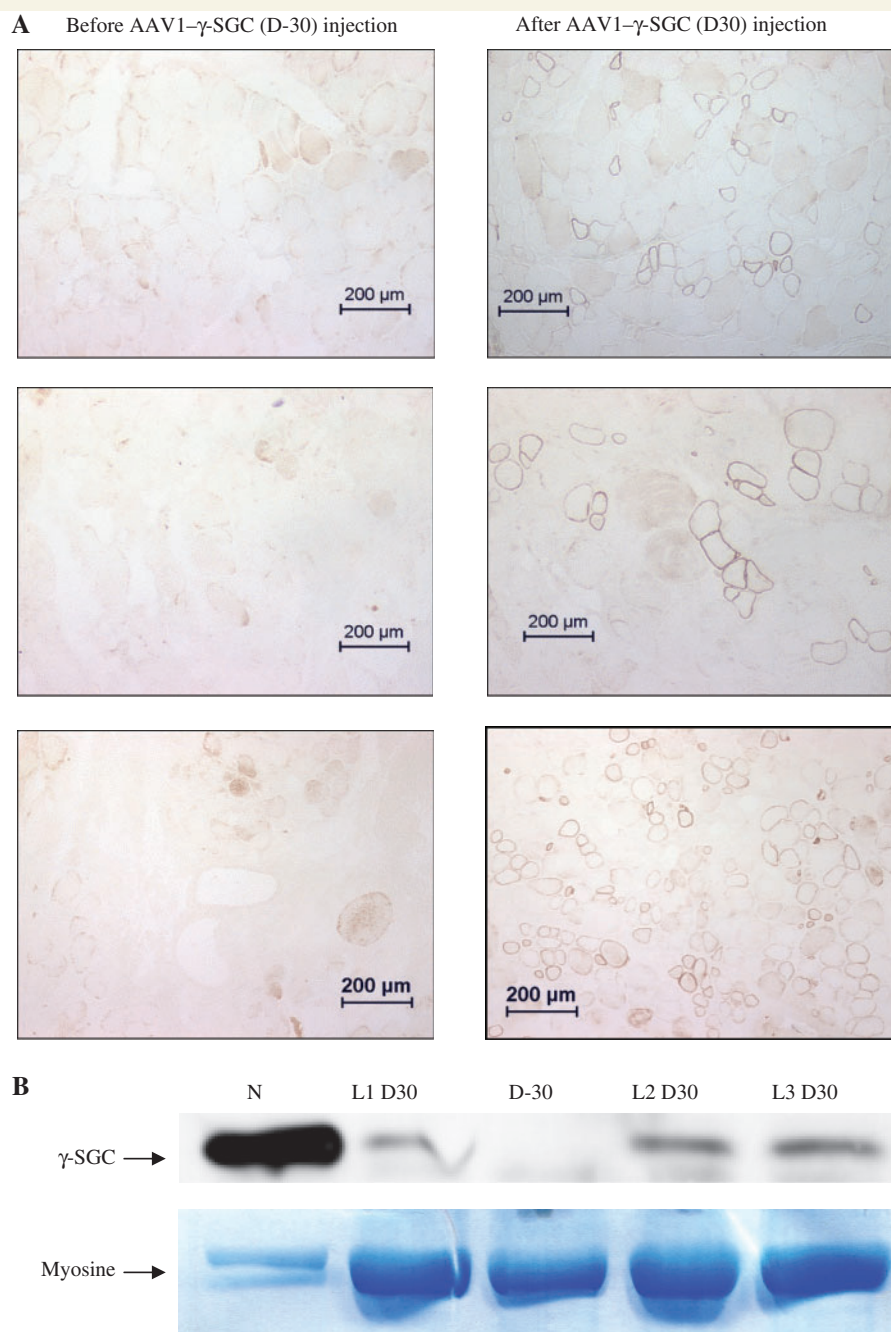


Figure 3 (A) Immunohistochemical detection of exogenous γ -SGC in the muscle biopsy specimens from the three patients who received the highest dose of AAV1.des.h γ -SGC (4.5×10^{10} viral genomes intramuscularly). Muscle biopsies were performed at Day -30 in the dominant extensor carpi radialis muscle and Day 30 in the non-dominant extensor carpi radialis muscle. AAV1.des.h γ -SGC was injected in the latter at Day 0. (B) Western blot detection of exogenous γ -SGC in Patient 9 muscle lysate. The first lane corresponds to normal control muscle (N). The next lane corresponds to a first level of section of a muscle biopsy specimen obtained 30 days after AAV1.des.h γ -SGC injection (L1 D 30). The next lane corresponds to a representative level of section of the muscle biopsy specimen obtained 30 days before AAV1.des.h γ -SGC injection (D -30). The following two lanes correspond to two other levels of section of the muscle biopsy specimen obtained 30 days after AAV1.des.h γ -SGC injection (L2 D 30, L3 D 30). (C) Immunohistochemical detection at Day 30 of γ , α and β -SGC on serial sections of muscle biopsy specimen of non-dominant extensor carpi radialis muscle from Patient 8 who received the highest dose of AAV1.des.h γ -SGC (4.5×10^{10} viral genomes intramuscularly), illustrating the detection of the whole sarcoglycan complex. For comparison, the same complex is shown at Day -30 in the dominant extensor carpi radialis muscle, before any AAV1.des.h γ -SGC injection.

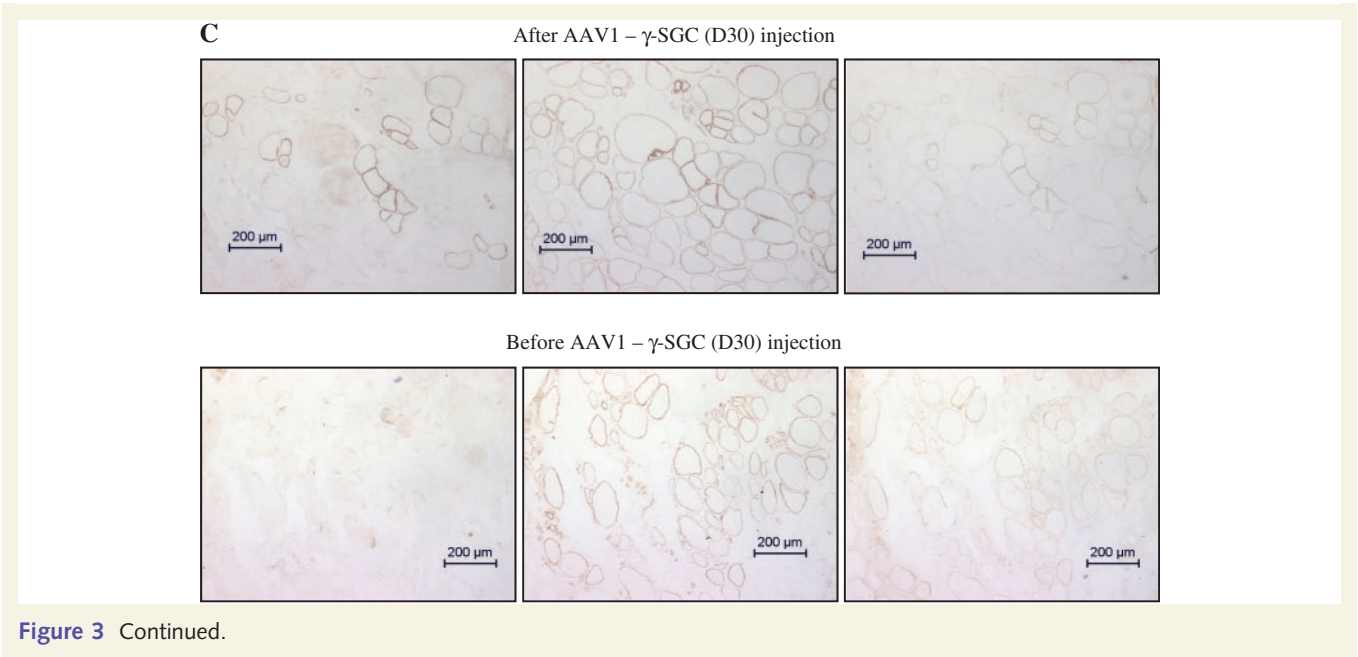
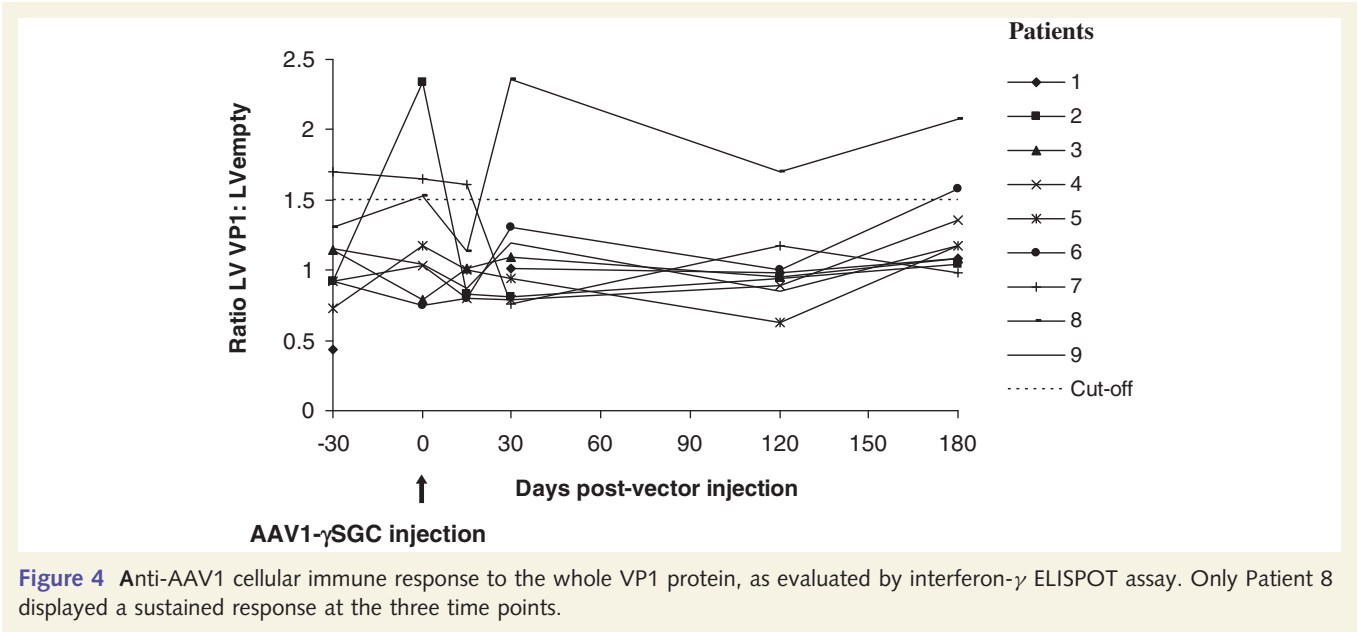


Table 2 Anti-AAV1 and (neutralizing) antibody titres

Patients	Day –30	Day 0	Day 15	Day 30	Day 120	Day 180
01	UD	NA	NA	1/90 (UD)	1/270 (UD)	1/90 (UD)
02	1/810 (1/20)	1/270 (1/20)	1/21870 (1/1600)	1/21870 (1/1600)	1/7290 (1/800)	1/7290 (1/800)
03	UD	UD	UD	UD	1/90 (UD)	1/30 (UD)
04	UD	UD	UD	UD	1/90 (UD)	1/90 (UD)
05	1/810 (1/800)	1/2430 (1/800)	1/2430 (1/1600)	1/7290 (1/1600)	1/7290 (1/800)	1/2430 (1/400)
06	1/270 (1/20)	1/810 (1/20)	1/2430 (1/800)	1/2430 (1/800)	1/2430 (1/200)	1/2430 (1/200)
07	UD	1/30 (UD)	1/2430 (1/200)	1/2430 (1/20)	1/2430 (1/200)	1/2430 (1/20)
P08	UD	UD	1/30 (UD)	1/30 (1/20)	1/270 (UD)	1/270 (UD)
P09	UD	UD	1/90 (UD)	1/270 (UD)	1/270 (1/20)	1/270 (1/20)

AAV1.des.h γ -SGC was injected in the non-dominant extensor carpi radialis muscle at Day 0. The humoral response to AAV1 was measured on serial dilutions of heat-inactivated serum at different dates from Days –30 to 180. NA = not applicable; UD = undetectable.



capsid proteins may lead to a loss of transgene expression by lysing transduced cells (Mingozzi *et al.*, 2009). In the study of six patients with limb girdle muscular dystrophy type 2D, an anti-capsid response was observed in three subjects after AAV1 vector injection (Mendell *et al.*, 2009, 2010). However, five patients exhibited MHC-class I antigen overexpression at the surface of their muscle fibres, as well as inflammatory cell infiltration, indicating a local cellular response to AAV and/or to the exogenous protein (Mendell *et al.*, 2009, 2010). Only one of our patients (Patient 8), who received the highest dose, had a persistently detectable cytotoxic T lymphocyte response, from Days 30 to 180. Contrary to previous studies, we observed no concomitant creatine kinase elevation, MHC-class I overexpression, or inflammatory infiltration. The cellular response in Patient 8 did not appear to correlate with the strength of the humoral response. This discrepancy in the frequency of detectable cellular immune responses in different clinical studies may be explained by differences in the AAV dose (Mingozzi *et al.*, 2009). Another important factor may be the quality (purity) of the vector preparation (Wright, 2009). Finally, intramuscular AAV delivery is consistently more immunogenic than intravenous delivery (Toromanoff *et al.*, 2010).

Our findings represent proof of concept for γ -SGC replacement therapy in patients with limb girdle muscular dystrophy type 2C. Further research will be needed to achieve widespread vector delivery, using locoregional (Hegge *et al.*, 2010) or, ultimately, systemic delivery of AAV γ -SGC vectors.

Acknowledgements

We thank the steering committee members, Drs Gilbert Bensimon, Marc Pierredon, Jon Andoni Urtizberea for their insightful suggestions concerning the study protocol. We also thank Adeline Dor, Isabelle Adamski, Drs Serge Braun, Philippe Moullier, Marie-Hélène Fievet, Virginie Monteilhet, Sylvie Boutin and Patrice Denéfle for their help in various aspects of the study.

Funding

Association Française contre les Myopathies (AFM); Advanced Diagnostics for New Therapeutic Approaches (ADNA) and Genethon, Evry, France.

Conflict of interest

Some coauthors are employees of Genethon, the company sponsor of the study.

References

Bainbridge JW, Smith AJ, Barker SS, Robbie S, Henderson R, Balaggan K, et al. Effect of gene therapy on visual function in Leber's congenital amaurosis. *N Engl J Med* 2008; 358: 2231–9.

- Ben Hamida M, Ben Hamida C, Zouari M, Belal S, Hentati F. Limb-girdle muscular dystrophy 2C: clinical aspects. *Neuromuscul Disord* 1996; 6: 493–4.
- Boutin S, Monteilhet V, Veron P, Leborgne C, Benveniste O, Montus MF, et al. Prevalence of serum IgG and neutralizing factors against adeno-associated virus (AAV) types 1, 2, 5, 6, 8, and 9 in the healthy population: implications for gene therapy using AAV vectors. *Hum Gene Ther* 2010; 21: 704–12.
- Brantly ML, Chulay JD, Wang L, Mueller C, Humphries M, Spencer LT, et al. Sustained transgene expression despite T lymphocyte responses in a clinical trial of rAAV1-AAT gene therapy. *Proc Natl Acad Sci USA* 2009; 106: 16363–8.
- Bushby KM, Beckmann JS. The limb-girdle muscular dystrophies—proposal for a new nomenclature. *Neuromuscul Disord* 1995; 5: 337–43.
- Calvo F, Teixeira S, Fernandez JM, Teijeiro A, Fernandez-Hojas R, Fernandez-Lopez XA, et al. Evaluation of heart involvement in gamma-sarcoglycanopathy (LGMD2C). A study of ten patients. *Neuromuscul Disord* 2000; 10: 560–6.
- Cideciyan AV, Aleman TS, Boye SL, Schwartz SB, Kaushal S, Roman AJ, et al. Human gene therapy for RPE65 isomerase deficiency activates the retinoid cycle of vision but with slow rod kinetics. *Proc Natl Acad Sci USA* 2008; 105: 15112–7.
- Cordier L, Hack AA, Scott MO, Barton-Davis ER, Gao G, Wilson JM, et al. Rescue of skeletal muscles of gamma-sarcoglycan-deficient mice with adeno-associated virus-mediated gene transfer. *Mol Ther* 2000; 1: 119–29.
- Hack AA, Ly CT, Jiang F, Clendenin CJ, Sigrist KS, Wollmann RL, et al. Gamma-sarcoglycan deficiency leads to muscle membrane defects and apoptosis independent of dystrophin. *J Cell Biol* 1998; 142: 1279–87.
- Hegge JO, Wooddell CI, Zhang G, Hagstrom JE, Braun S, Huss T, et al. Evaluation of hydrodynamic limb vein injections in nonhuman primates. *Hum Gene Ther* 2010; 21: 829–42.
- Heilbronn R, Weger S. Viral vectors for gene transfer: current status of gene therapeutics. *Handb Exp Pharmacol* 2010; 197: 143–70.
- Jaski BE, Jessup ML, Mancini DM, Cappola TP, Pauly DF, Greenberg B, et al. Calcium upregulation by percutaneous administration of gene therapy in cardiac disease (CUPID Trial), a first-in-human phase 1/2 clinical trial. *J Card Fail* 2009; 15: 171–81.
- Kaplitt MG, Feigin A, Tang C, Fitzsimons HL, Mattis P, Lawlor PA, et al. Safety and tolerability of gene therapy with an adeno-associated virus (AAV) borne GAD gene for Parkinson's disease: an open label, phase I trial. *Lancet* 2007; 369: 2097–105.
- Kefi M, Amouri R, Driss A, Ben Hamida C, Ben Hamida M, Kunkel LM, et al. Phenotype and sarcoglycan expression in Tunisian LGMD 2C patients sharing the same del521-T mutation. *Neuromuscul Disord* 2003; 13: 779–87.
- Maguire AM, High KA, Auricchio A, Wright JF, Pierce EA, Testa F, et al. Age-dependent effects of RPE65 gene therapy for Leber's congenital amaurosis: a phase 1 dose-escalation trial. *Lancet* 2009; 374: 1597–605.
- Maguire AM, Simonelli F, Pierce EA, Pugh EN Jr, Mingozzi F, Bennicelli J, et al. Safety and efficacy of gene transfer for Leber's congenital amaurosis. *N Engl J Med* 2008; 358: 2240–8.
- Manno CS, Chew AJ, Hutchison S, Larson PJ, Herzog RW, Arruda VR, et al. AAV-mediated factor IX gene transfer to skeletal muscle in patients with severe hemophilia B. *Blood* 2003; 101: 2963–72.
- Manno CS, Pierce GF, Arruda VR, Glader B, Ragni M, Rasko JJ, et al. Successful transduction of liver in hemophilia by AAV-Factor IX and limitations imposed by the host immune response. *Nat Med* 2006; 12: 342–7.
- Mendell JR, Campbell KJ, Rodino-Klapac LR, Sahenk Z, Shilling C, Lewis S, et al. Dystrophin Immunity in Duchenne's muscular dystrophy. *N Engl J Med* 2010; 363: 1429–37.
- Mendell JR, Rodino-Klapac LR, Rosales-Quintero X, Kota J, Coley BD, Galloway G, et al. Limb-girdle muscular dystrophy type 2D gene therapy restores alpha-sarcoglycan and associated proteins. *Ann Neurol* 2009; 66: 290–7.

- Mendell JR, Rodino-Klapac LR, Rosales XQ, Coley BD, Galloway G, Lewis S, et al. Sustained alpha-sarcoglycan gene expression after gene transfer in limb-girdle muscular dystrophy, type 2D. *Ann Neurol* 2010; 68: 629–38.
- Merlini L, Kaplan JC, Navarro C, Barois A, Bonneau D, Brasa J, et al. Homogeneous phenotype of the gypsy limb-girdle MD with the gamma-sarcoglycan C283Y mutation. *Neurology* 2000; 54: 1075–9.
- Mingozzi F, Meulenberg JJ, Hui DJ, Basner-Tschakarjan E, Hasbrouck NC, Edmonson SA, et al. AAV-1-mediated gene transfer to skeletal muscle in humans results in dose-dependent activation of capsid-specific T cells. *Blood* 2009; 114: 2077–86.
- Moss RB, Milla C, Colombo J, Accurso F, Zeitlin PL, Clancy JP, et al. Repeated aerosolized AAV-CFTR for treatment of cystic fibrosis: a randomized placebo-controlled phase 2B trial. *Hum Gene Ther* 2007; 18: 726–32.
- Ozawa E, Noguchi S, Mizuno Y, Hagiwara Y, Yoshida M. From dystrophinopathy to sarcoglycanopathy: evolution of a concept of muscular dystrophy. *Muscle Nerve* 1998; 21: 421–38.
- Riviere C, Danos O, Douar AM. Long-term expression and repeated administration of AAV type 1, 2 and 5 vectors in skeletal muscle of immunocompetent adult mice. *Gene Ther* 2006; 13: 1300–8.
- Romero NB, Braun S, Benveniste O, Leturcq F, Hogrel JY, Morris GE, et al. Phase I study of dystrophin plasmid-based gene therapy in Duchenne/Becker muscular dystrophy. *Hum Gene Ther* 2004; 15: 1065–76.
- Stroes ES, Nierman MC, Meulenberg JJ, Franssen R, Twisk J, Henny CP, et al. Intramuscular administration of AAV1-lipoprotein lipase S447X lowers triglycerides in lipoprotein lipase-deficient patients. *Arterioscler Thromb Vasc Biol* 2008; 28: 2303–4.
- Toromanoff A, Adjali O, Larcher T, Hill M, Guigand L, Chenuaud P, et al. Lack of immunotoxicity after regional intravenous (RI) delivery of rAAV to nonhuman primate skeletal muscle. *Mol Ther* 2010; 18: 151–60.
- Wright JF. Transient transfection methods for clinical adeno-associated viral vector production. *Hum Gene Ther* 2009; 20: 698–706.